



Changes in Fertility and Morphology of Sensitized Rat Uterine Endometrium upon an Intra-uterine Injection of Antigen

Jan Friberg & Ove Nilsson

To cite this article: Jan Friberg & Ove Nilsson (1972) Changes in Fertility and Morphology of Sensitized Rat Uterine Endometrium upon an Intra-uterine Injection of Antigen, Upsala Journal of Medical Sciences, 77:3, 133-135, DOI: [10.1517/03009734000000019](https://doi.org/10.1517/03009734000000019)

To link to this article: <https://doi.org/10.1517/03009734000000019>



Published online: 02 Mar 2011.



Submit your article to this journal [↗](#)



Article views: 157



View related articles [↗](#)

Changes in Fertility and Morphology of Sensitized Rat Uterine Endometrium upon an Intra-uterine Injection of Antigen

JAN FRIBERG and OVE NILSSON

Department of Obstetrics and Gynecology, University Hospital, Uppsala, and Department of Anatomy, Uppsala, Sweden

ABSTRACT

Rats were immunized with BCG-vaccine or horse serum and divided into two subgroups, one containing pregnant animals, the other containing spayed animals treated with progesterone. The pregnant rats were given an intra-uterine injection of the antigen on day 3 of pregnancy and the number of foetuses was registered. The spayed rats were first given progesterone, then an intra-uterine injection of the antigen, and prepared for microscopy at various intervals. The results showed that an intra-uterine injection of BCG-vaccine rendered implantation impossible and also markedly changed the structure of the endometrium. Serum, in the corresponding experiments, did not block implantation, but morphological signs of an immune reaction were present although not in the uterine epithelium. It is concluded that with the design used, an immunological reaction of the immediate-type cannot change the structure and function of the uterine epithelium sufficiently to render implantation impossible.

INTRODUCTION

Various experiments with systemic immunization of female animals with testicular tissue or spermatozoa have been made. Most of the published results have indicated a lowered fertility of the animal after the immunization (1–5). The results point to the uterus as the site of some process that lowers fertility (4), probably in the form of an impaired nidation (3).

It is not known, however, to what degree the endometrium is affected by an immune reaction. Therefore, the aim of the present experiments was to correlate fertility and endometrial morphology during an immune reaction, locally provoked in the endometrium at early pregnancy. The paper reports the influence of an intra-uterine injection of an antigen during both the delayed-type and the immediate-type of allergy.

To obtain standardized conditions, the morphology has been examined mainly in a state equivalent to preimplantation, namely in the spayed progesterone-treated animal.

METHOD

The immunization with BCG-vaccine was undertaken with a single intracutane injection. A tuberculin test was performed 4 weeks after the immunization, and only strongly tuberculin-positive animals were used in the experiments. The immunization with serum was started with a subcutane injection of a mixture of 0.5 ml horse serum and 0.5 ml pertussis vaccine (SBL, Stockholm) followed 3 days later by 1 ml horse serum which also was injected subcutaneously. Four weeks later the efficacy of the immunization was tested by giving some animals an intraperitoneal injection of 0.5 ml serum. All these animals got an anaphylactic response.

The experimentation was performed 4–6 weeks after the immunizations. Each group of animals immunized with BCG-vaccine or horse serum was further divided into two subgroups, one containing pregnant animals, the other containing spayed animals treated with progesterone. Non-immunized controls were taken to each sub-group.

The pregnant animals were given an injection of 0.05 ml BCG-vaccine or serum in one uterine horn on day 3 of pregnancy and the number of foetuses in both the horns was registered sometimes during days 10–16. (Day 1 being the day of finding vaginal sperm cells.) A total of 5 non-vaccinated and 5 BCG-vaccinated rats, 8 non-immunized and 11 serum-immunized, were used.

The spayed animals were given progesterone for 4 days (5 mg/day) and then an injection of 0.05 ml BCG-vaccine or serum, in one uterine horn while the other uterine horn served as a control. These animals were prepared for microscopy 0, 6, 12 hours, 2 and 6 days after the intra-uterine injection, being given progesterone each day. Each group contained at least 3 animals. The preparation for microscopy comprised an aortic perfusion with glutaraldehyde and embedding in Epon. The specimens were examined with light and electron microscopy.

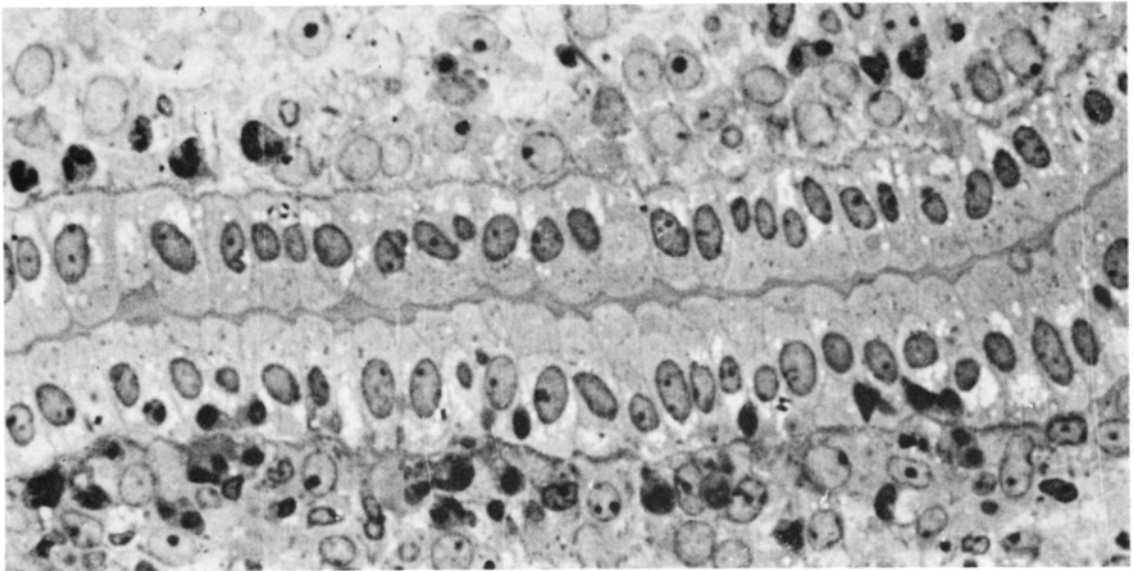


Fig. 1. Endometrium of a spayed serum-immunized rat, injected with progesterone and given antigen intraluminally 12 hrs before the fixation. Several leucocytes are observed. $\times 1\,000$.

RESULTS

The results showed that an intra-uterine injection of BCG-vaccine to both vaccinated and non-vaccinated animals rendered implantation impossible. An intra-uterine injection of serum to both immunized and non-immunized animals did not block implantation. However, the fertility rate seems to have been lowered but the material does not permit a statistical evaluation.

Spayed progesterone-treated animals, vaccinated with BCG, showed a leucocytic response upon an intra-uterine injection of BCG, but a similar

although less intense reaction also occurred among the non-immunized animals injected with BCG. Electron microscopy of the vaccinated animals upon the intra-uterine injection of BCG demonstrated marked changes in the uterine epithelium. It generally displayed many long microvilli, an extensive development of the Golgi apparatus and of the granular endoplasmic reticulum, and an appearance of large vacuoles but a disappearance of those apical vesicles being characteristic for a normal preimplantation stage in the rat (6-7). A similar change also occurred

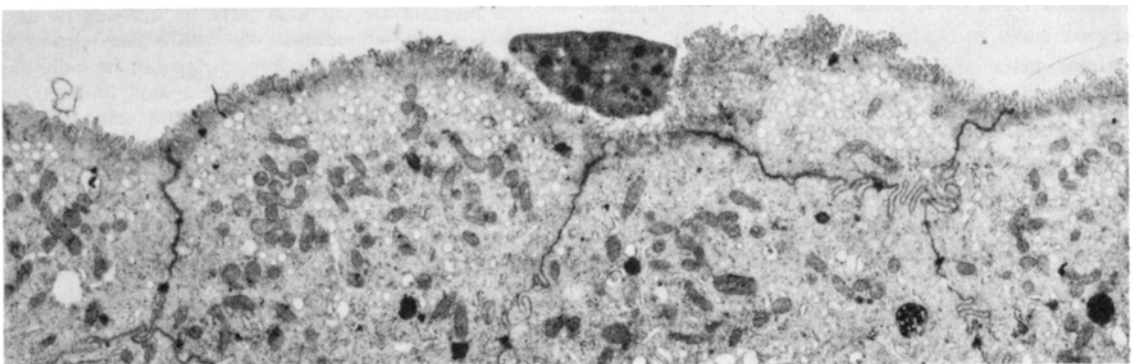


Fig. 2. Uterine luminal epithelium of a spayed serum-immunized rat, injected with progesterone and given antigen intraluminally 12 hrs before the fixation. The epithelium possesses regular microvilli and many apical vesicles. Some leucocytes are present in the lumen. $\times 4\,000$.

in most non-vaccinated animals, but no attempts have been made to differ the immune component of the reaction from the unspecific one.

Spayed progesterone-treated animals, immunized with serum, showed 6 hours after the intra-uterine injection of serum a leucocyte infiltration all along the horns. Gradually, the amount of secretion in the lumen increased and became rich in leucocytes (Fig. 1). Electron microscopy of the uterine epithelium, however, did not reveal any obvious changes compared with the appearance of the epithelium in the control animals (Fig. 2).

CONCLUSION

The conclusion is that although the endometrium as a whole shows immune reactions during both the delayed-type and immediate-type of hypersensitivity, the reactivity of its various components differs. Thus, in the immediate-type, the ultrastructure of the uterine epithelium is hardly changed. This rather unchanged appearance of the immunized epithelium, although being influenced by antigen, correlates well with its retained capacity to permit implantations. Thus, with the design used an immunological reaction of the immediate-type cannot change the structure and function of the uterine epithelium sufficiently to render implantation impossible.

ACKNOWLEDGEMENTS

Part of this study was reported at the VI Acta Endocrinologica Congress in Helsinki 1967. The experiments were supported by the Swedish Medical Research Council (project no. 12X-70) and by the Ford Foundation (grant no. 66-405 to Professor Carl Gemzell). Technical assistant: Miss Kerstin Rystedt.

REFERENCES

1. Behrman, S. J.: Immunological aspects of fertility and infertility. In Symposium "Agents Affecting Fertility" (ed. C. R. Austin & J. S. Perry), pp. 47-61. J. & A. Churchill Ltd., London, 1965.
2. Behrman, S. J.: The immune response and infertility: Experimental evidence. In Progress in Infertility (ed. S. J. Behrman & R. W. Kistner), pp. 675-699. Little, Brown & Co., Boston, 1968.
3. Hilfrich, H. J., Larsen, R. & Siedentopf, H. G.: Untersuchungen über die immunologische Fertilitätsbeeinträchtigung bei Kaninchen. Arch Gynäk 210: 293, 1971.

4. Katsh, S.: Demonstration in vitro of anaphylactoid response of the uterus and ileum of guinea pigs injected with testis or sperm. J exp Med 107: 95, 1958.
5. Katsh, S. & Katsh, G. F.: Perspectives in immunological control of reproduction: Past, present and future. Pacific Med Surg 73: 28, 1965.
6. Ljungkvist, I. & Nilsson, O.: Ultrastructure of rat uterine luminal epithelium at functional states compatible with implantation. Z Anat EntwGesch 135: 101, 1971.
7. Nilsson, O.: Structural differentiation of luminal membrane in rat uterus during normal and experimental implantations. Z Anat EntwGesch 125: 152, 1966.

Received June 28, 1972

Address for reprints:

Jan Friberg, M.D.
Department of Obstetrics & Gynecology
University Hospital
S-750 14 Uppsala 14
Sweden