Acta Radiologica

ISSN: 0001-6926 (Print) (Online) Journal homepage: informahealthcare.com/journals/iaro20

Normal Variations of the Left Kidney

J. Frimann-Dahl

To cite this article: J. Frimann-Dahl (1961) Normal Variations of the Left Kidney, Acta Radiologica, 55:3, 207-216, DOI: 10.3109/00016926109174541

To link to this article: https://doi.org/10.3109/00016926109174541

Published online: 14 Dec 2010.

FROM THE ROENTGEN DEPARTMENT (DIRECTOR: PROF. J. FRIMANN-DAHL), ULLEVÅL HOSPITAL, OSLO, NORWAY.

NORMAL VARIATIONS OF THE LEFT KIDNEY

An anatomical and radiologic study

by

J. FRIMANN-DAHL

The kidneys are parenchymatous organs situated in the retroperitoneal space close to the posterior abdominal wall at the level of the second and third lumbar vertebrae. PERNKOPF estimates the average size of the kidneys as 12 cm long, 6 cm broad and 3 cm thick, and states that there is a certain difference in shape and size, the left kidney being somewhat larger than the right. The weight varies from 150 to 200 g. The axis of the kidney is obliquely positioned in both the sagittal and frontal planes and lies parallel to the surface of the psoas muscle. Its position varies with the contraction of the psoas and also with the respiratory movements of the diaphragm.

The kidneys are described in anatomical textbooks as a pair of almost symmetrical organs. It is indicated, however, that there are some small differences between the right and the left kidney. It is well known that the left kidney lies from 1 to 10 cm higher than the right but normally this arrangement may be reversed, with the right kidney a little higher than the left. The kidney is situated more caudally on the right side than on the left, mainly because the liver intervenes and occupies most of the right hypochondrium.

The dorsal surface of the kidney is in contact with the posterior abdominal wall, lying against the psoas muscle, the diaphragm, and the quadratus lumborum muscle. On the posterior surface there are some more or less marked

Submitted for publication 3 May 1960.

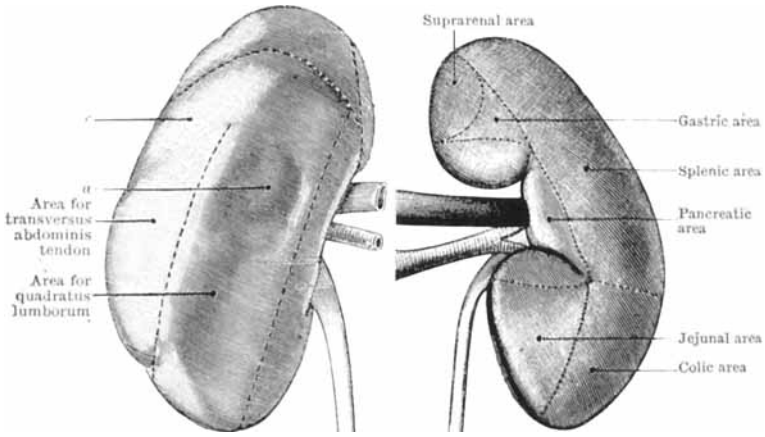

Fig. 1. a) Dorsal aspect of left kidney. Slight impressions caused by muscles and tendons upon which the kidney rests. *c* — impression of the last rib. b) Ventral surface of the left kidney showing different areas of neighbouring organs.

depressions caused by the muscles and tendons upon which the kidneys rest. When the kidney is fixed and hardened before removal, smooth elevations and ridges are occasionally observed, but usually they are not sharply defined. According to CUNNINGHAM, there is in addition to these facets on the posterior aspect often a small groove for the last rib, one for the lumbo-costal arch, and two or three minor depressions for the upper transverse processes of the lumbar vertebrae (Fig. 1a).

The ventral syntopy (Fig. 1b) is more complicated. On the right side the liver overlies the kidney anteriorly and laterally and only the posterior part is in contact with the kidney, forming the area hepatica. There is sometimes a duodenal area as well.

On the anterior surface of the left kidney three more or less defined flattened impressions are found. One of these is the splenic impression. The spleen is usually in contact with the kidney on its lateral and anterior border, but this varies largely according to the size of the spleen. Occasionally the tail of the pancreas may intervene, partly separating these organs (Fig. 2). The pancreas sometimes touches the upper pole of the kidney so that this area is slightly flattened. The stomach is only partly in contact with the kidney since the pancreas and part of the suprarenal gland intervene. Extending downwards to the lower end of the kidney is a facet for the jejunum and the colon. CUNNINGHAM further states that it is common to find the left kidney thicker and less flattened anteroposteriorly than the right, with the impressions upon its surface better marked. In this connection the fixation of the kidneys may also be mentioned.

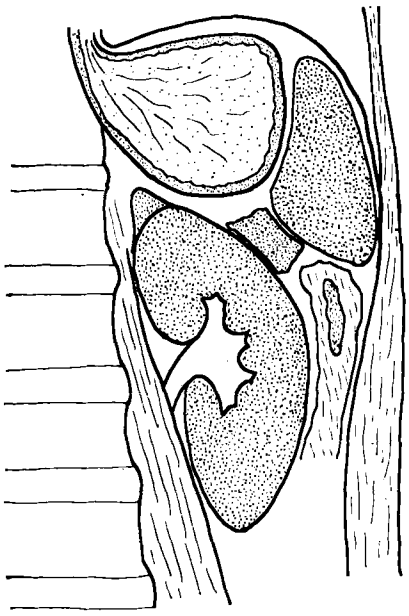

Fig. 2. Schematic drawing showing pancreas intervening between the kidney and spleen (modified after PERNKOPF).

The fact that a floating kidney is more rarely encountered on the left than on the right side is probably associated with this feature. The fixation of the left kidney may also be explained by the fact that it is anchored by its main artery, which is shorter than the right (the vein is longer on the left side).

LÖFGREN, in his anatomical studies, showed that the kidney could be divided in three lobes corresponding to three segments; there were three calyces (and pyramids) in the upper lobe, two in the middle lobe (double pair, ventral and dorsal), and two in the lower lobe. BOIJSEN used a similar classification in his anatomical studies of the vascular pattern. The same division has been adopted by SEMB and FRIMANN-DAHL in various works on diseases of the kidneys.

Roentgen appearances

MOËLL, in his roentgen study on the size of the kidneys, states that the kidneys are smaller in women than in men, and that in both sexes the left is somewhat larger than the right. In men he found the average dimensions to be 12.7 cm × 6.3 cm for the right kidney and 13.2 cm × 6.4 cm for the left, the total area being 129.6 cm^2 and the area per sq meter of the body surface 70.1 cm^2. The corresponding figures for women are 12.4 cm × 5.9 cm, 12.8 cm × 6.1 cm, and 119.3 cm^2, and 72.2 cm^2, respectively.

In conventional pyelography only the pelvis and the calyces are properly demonstrated. The parenchyma and the outer contour are better shown by urography, and particularly if the ureter is blocked as for instance in cases of ureteric stones. Due to accumulation of the contrast medium a so-called nephrographic effect is obtained and this provides an opportunity to determine the outer contour and shape of the kidney. By aortography a similar 'loading' of the parenchyma may be observed and the spleen is also rendered opaque (Fig. 3). Selective renal angiography produces more marked density (Fig. 4a) and the size and shape of the kidneys may be studied accurately; oblique views may prove of value (Fig. 4b). This procedure has in turn stimulated the study of the vascular anatomy of the kidneys, including the cortical pattern.

The present study is based on a series of 250 selective renal angiographies and an estimated 5 950 urographies carried out over the last three years.

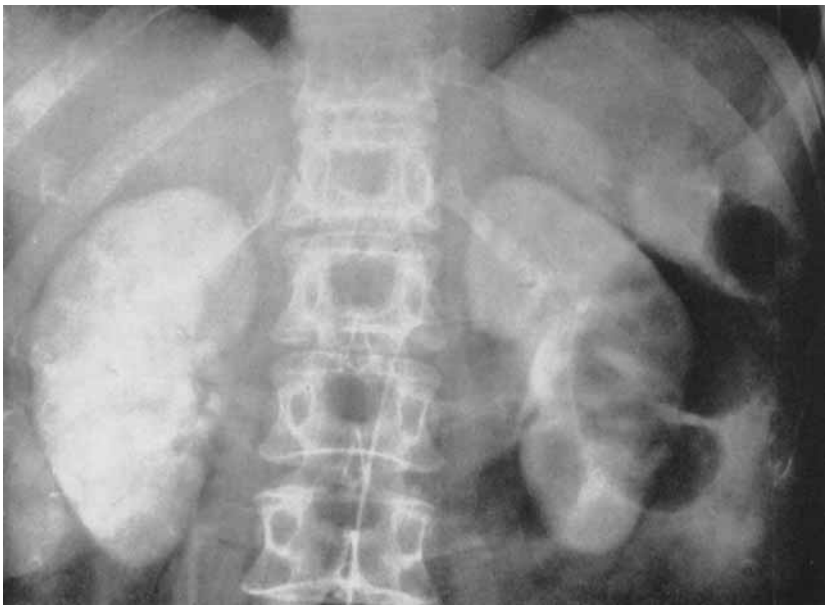

Fig. 3. Urography in the course of aortography. Contrast medium in the kidneys and spleen.

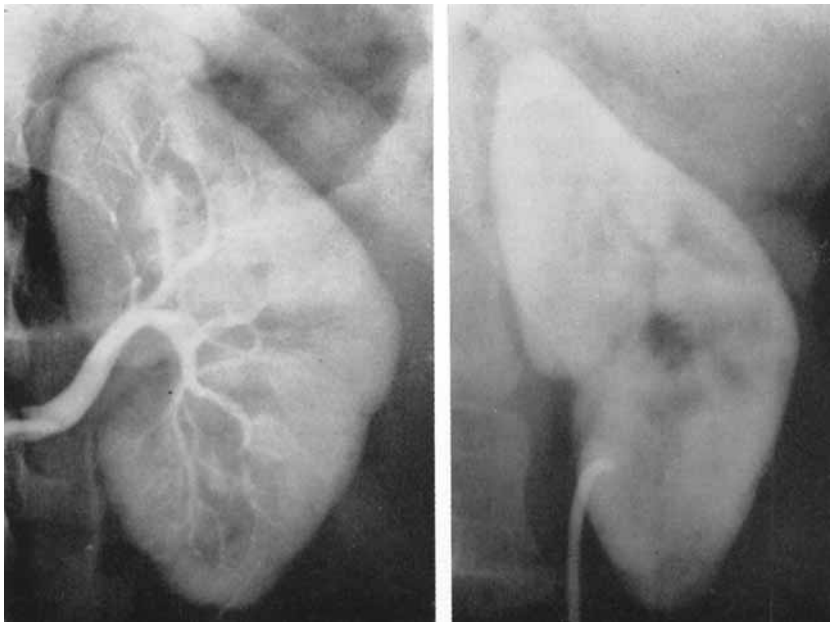

a b

Fig. 4. a) Selective renal angiography showing bulging of the lateral contour. b) Lateral view of kidney.

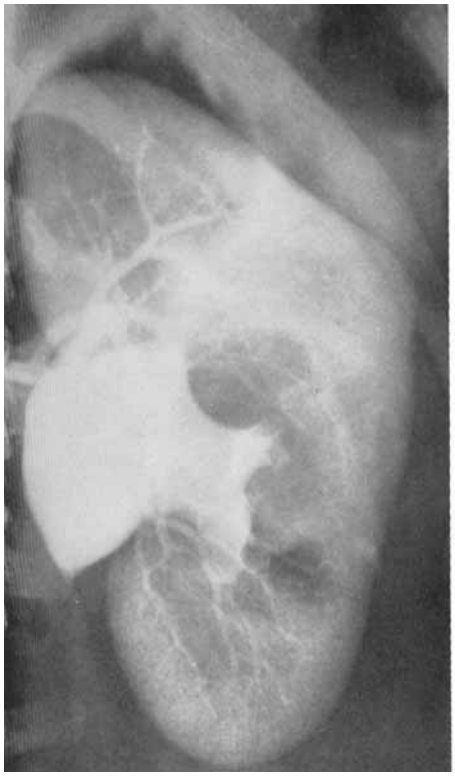

Fig. 5. Marked 'bump' in a relatively large kidney and small spleen.

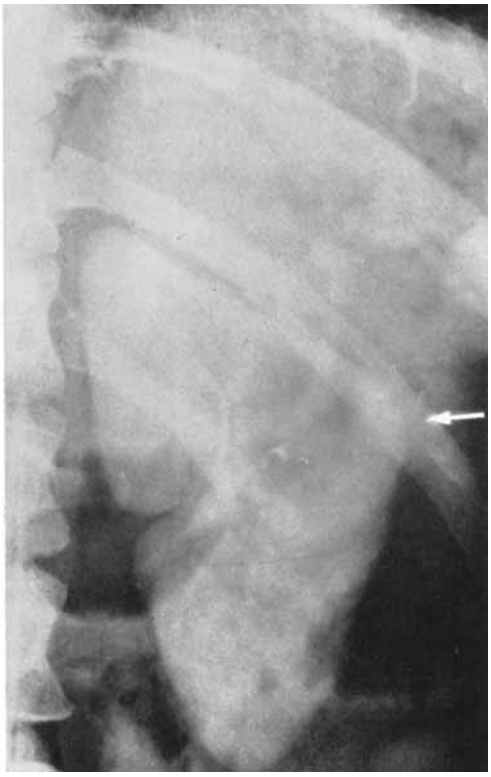

Fig. 6. Bulging of lateral contour in a relatively small kidney and a large spleen.

The study indicates that in about 10 per cent of cases the left kidney has a more or less marked 'bulging' which may vary in position along the lateral border. It is usually most conspicuous in the middle segment and when marked gives the kidney an almost triangular form (Fig. 5).

The bulge is most evident in adults and in the normal-sized kidney, but even in small children a tendency to a similar deformity may be observed. In practically all cases where this deformity was present the spleen was lying closely adjacent with its renal facies parallel to the lateral border of the kidney. The lower pole of the spleen was placed just above and lateral to the elevation or 'bump' (Fig. 6). The obvious explanation therefore seems to be that the kidney in these cases 'has to carry the spleen on its back' and consequently an indentation is formed, so marked that a tumor-like elevation occurs. If unrecognized, this deformity may easily be mistaken for a cyst or even a malignant tumor. In cases of unexplained hematuria and a coincidental 'bulging' of the left

kidney, for example, misinterpretation may easily be made (Fig. 7).

Another important feature is that the kidney pelvis also shows a 'normal' anatomical variation which corresponds to the deformity of the lateral contour. The pelvis may be only slightly influenced but the calyces are often markedly changed. Different patterns observed in this material are presented in Fig. 8. As shown by the schematic drawings, it is mostly the calyces in the middle segment which are influenced. When the spleen is lying along the border, one or two calyces of the middle lobe are shortened and the kidney elongated. The lower middle calyx, which corresponds to the 'bulging', however, is elongated and larger than normal (Fig. 9). Occasionally the calyces of the upper and lower segments are also affected, being either compressed or elongated (Fig. 10). If the left kidney presents marked lobulation the bulging may be particularly accentuated (Fig. 11).

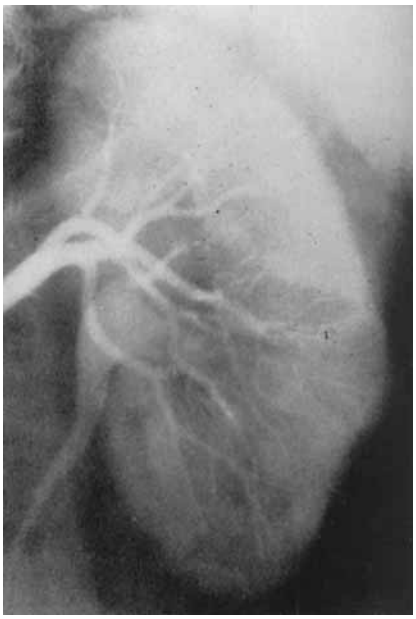

Fig. 7. Bulging of the left kidney. Differentiation from a cyst or tumor is important.

Amongst other possible causes of this deformity, the position of the pancreas must be taken into consideration. As illustrated earlier in the drawing in Fig. 2, the tail of the pancreas may intervene between the spleen and the left kidney. However, if the 'bump' could be explained as a pancreatic impression, one would expect an enlarged space between the spleen and the kidney in these cases. This has not been observed; on the contrary, the organs tend to lie closely adjacent. A third possibility is an impression caused by the 12th rib. As shown in Fig. 1a, a depression corresponding to the 12th rib is present but visible only on the posterior surface of the kidney and can therefore hardly interfere with the lateral contour. The roentgen findings have been scrutinized with this point in view and in many cases the 12th rib has been found to lie a considerable distance from the bulging or has been poorly developed. It therefore seems reasonable that this explanation may also be ruled out. The fact that the calyces are influenced by the deformity seems to prove that it must have developed early, probably at a fetal stage. A concise morphologic explanation cannot be offered in this study.

Whether the deformity of the left kidney is caused only by 'normal' spleens is a question difficult to answer and so is the question of the nature of the relationship in very small or enlarged spleens. Further experience is required. However, there is certainly a wide range of variation, for instance in cases in

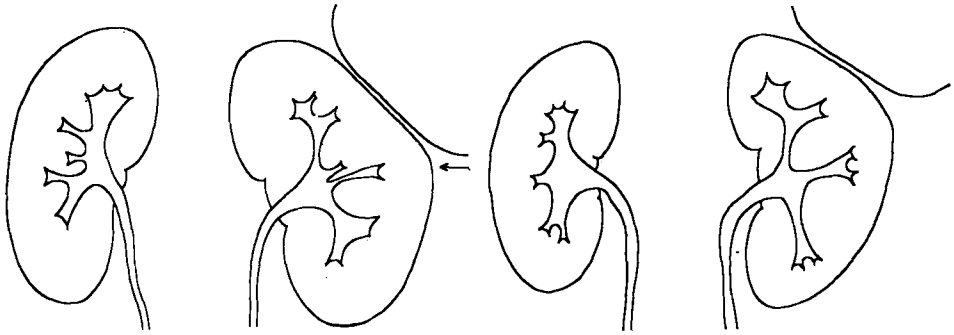

Fig. 8. Diagrammatic representations of typical normal variations of the calyces of the middle lobe of the left kidney.

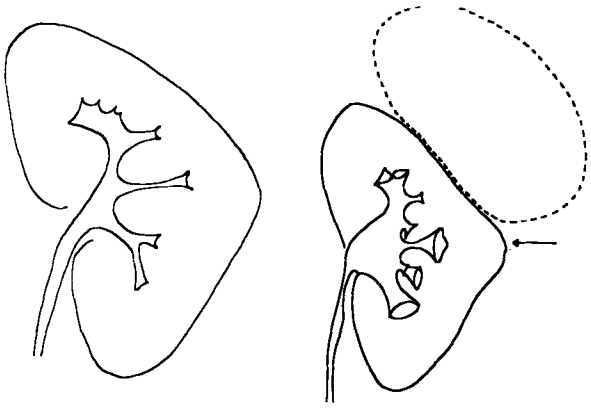

Fig. 9. Drawings showing influence of the spleen upon the renal pelvis.

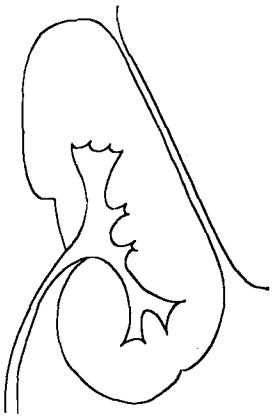

Fig. 10. Normal variation of the upper, middle and lower lobe calyces.

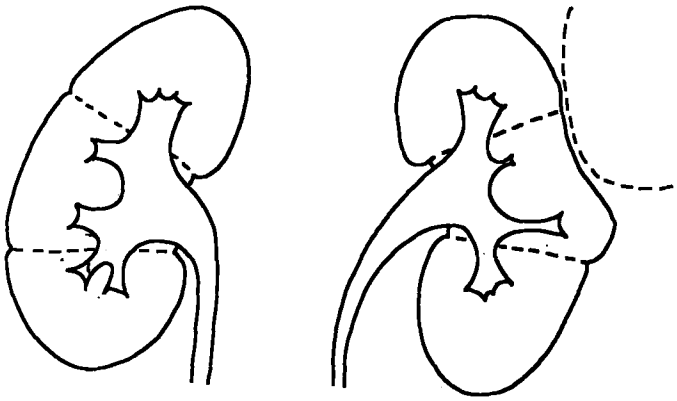

Fig. 11. Schematic drawing showing bulging of lateral contour of a lobulated left kidney.

Fig. 12. Enlarged upper pole of left kidney in combination with a small spleen.

which the spleen is nearly invisible and the left kidney lies close to the cupola of the diaphragm. The upper pole of the kidney may be correspondingly enlarged, having obviously encroached upon the space of the spleen. In such cases, the left kidney is much larger than the right (Fig. 12).

In other cases an enlarged spleen may have displaced the left kidney downwards and the deformity of the kidney which existed before the enlargement of the spleen is unchanged. Under these circumstances the left kidney is apt to be smaller than the right.

The fact that the spleen increases in size following a large intake of water has also been considered. It could have been that the deformity of the kidney was influenced secondarily by excessive fluid. We have investigated this possibility in some cases but so far no convincing results have been obtained.

Changes in the vascular pattern are, as a rule, not very conspicuous in relatively small bulgings; in other cases the vessels may be somewhat elongated or stretched in the area of the deformity (cf. Fig. 8). When there is a marked depression mainly of the upper lobe the vessels are shortened and tortuous (Fig. 13).

Finally, one may ask if a similar bulging occurs on the right side. It would not be surprising if the large overlying liver caused a deformity of the right kidney but evidently the liver lies more anteriorly than the spleen and does not

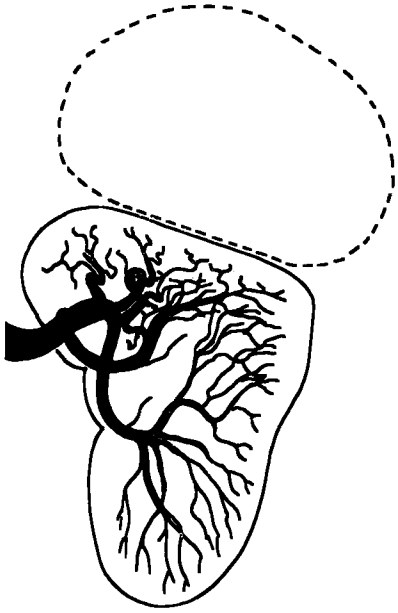

Fig. 13. Diagrammatic representation of the vascular pattern in a kidney with a marked splenic impression.

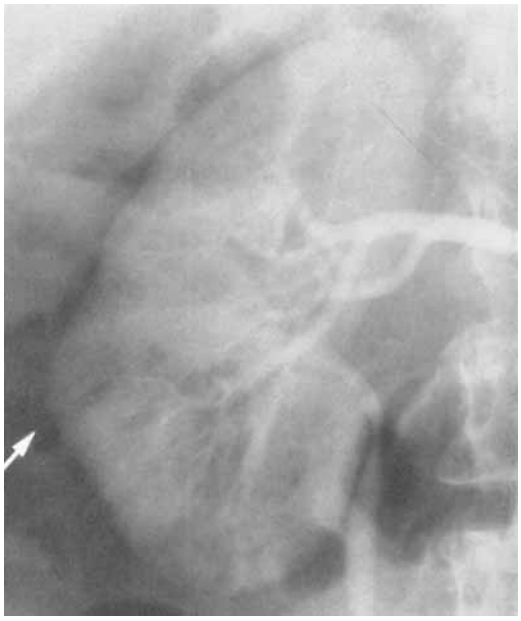

Fig. 14. Bulging of lateral contour of right kidney (one of the few observed in the period of the investigation).

influence the right kidney in the same way. In this series only one case of marked 'bulging' of the right kidney was observed, which to some extent was comparable to the findings on the left side (Fig. 14).

As far as the author is aware these observations on the appearances of the lateral contour of the left kidney and, in many cases, corresponding deformity of the pelvis and calyces and changes in the vascular anatomy, have not previously been described.

SUMMARY

A peculiar deformity of the left kidney occurring in about 10 per cent of all cases is described. This consists in a bulging of the lateral contour of the kidney with corresponding changes in the calyces; in some cases the vascular pattern is also influenced. The deformity is probably secondary to an impression made by an overriding spleen.

ZUSAMMENFASSUNG

Eine eigentümliche Deformierung der linken Niere, wie man sie in ca. 10 % aller Fälle sieht, wird beschrieben. Es handelt sich um eine Ausbuchtung der lateralen Nierenkontur mit entsprechenden Kalyxveränderungen. In einigen Fällen besteht auch eine Beeinflussung des Gefässnetzes. Die Deformierung ist wahrscheinlich Folgeerscheinung einer Impression, die durch eine überreitende Milz verursacht wird.

RÉSUMÉ

L'auteur décrit une déformation particulière du rein gauche qui existe dans environ 10 pour cent des cas. Elle consiste en une saillie du contour latéral du rein, avec des modifications correspondantes des calices; dans certains cas, la disposition des vaisseaux est, elle aussi, modifiée. Cette déformation est probablement secondaire à une empreinte splénique.

REFERENCES

Boijsen, E.: Angiographic studies of the anatomy of single and multiple renal arteries. Acta radiol. (1955) Suppl. No. 183.

Cunningham, D. J.: Textbook of anatomy. Henry Frowde and Hodder & Stoughton. Edinburgh, Glasgow and London 1917.

Frimann-Dahl, J.: Radiological investigations of urogenital tuberculosis. Urol. int. separatum 1 (1955), 396.

Löfgren, F.: Das topographische System der malpighischen Pyramiden der Menschenniere. Gleerups, Lund 1949.

Moëll, H.: Size of normal kidneys. Acta radiol. 46 (1956), 640.

Ödman, P.: Percutaneous selective angiography of the main branches of the aorta. Acta radiol. 45 (1956), 1.

Pernkopf, E.: Topographische Anatomie. Urban & Schwarzenberg, Berlin und Wien 1943.

Schrøder, E.: Kliniske studier over nyrefunktionen hos nephrectomerede (Danish). Diss. København 1944.

Semb, C.: The selective principle in the treatment of urogenital tuberculosis. Partial resection of the kidney and of the ureter. Urol. int. separatum 1 (1955), 359.