

Ankle arthrodesis using the Ilizarov apparatus: Good results in 6 patients

Michael Yanuka, Elisha Krasin, Michal Goldwirth, Zvi Cohen & Itzhak Otremski

To cite this article: Michael Yanuka, Elisha Krasin, Michal Goldwirth, Zvi Cohen & Itzhak Otremski (2000) Ankle arthrodesis using the Ilizarov apparatus: Good results in 6 patients, Acta Orthopaedica Scandinavica, 71:3, 297-300, DOI: [10.1080/000164700317411915](https://doi.org/10.1080/000164700317411915)

To link to this article: <https://doi.org/10.1080/000164700317411915>



Published online: 08 Jul 2009.



Submit your article to this journal [↗](#)



Article views: 300



View related articles [↗](#)



Citing articles: 4 View citing articles [↗](#)

Ankle arthrodesis using the Ilizarov apparatus

Good results in 6 patients

Michael Yanuka, Elisha Krasin, Michal Goldwirth, Zvi Cohen and Itzhak Otremski

Department of Orthopaedic Surgery "A", Tel Aviv Sourasky Medical Centre, 6 Weizman Street, Tel Aviv 64239, Israel.
Tel +972 3 697–3515. Fax –4671. E-mail: ekrasin@tasmc.health.gov.il. Correspondence: Dr. E. Krasin
Submitted 99-09-07. Accepted 00-01-07

ABSTRACT – We report our experience with the Ilizarov apparatus in performing ankle arthrodesis in 6 patients. The average age of the patients was 52 (42–60) years. 3 patients had posttraumatic arthrosis and active infection of the ankle or distal tibia and the other 3 had posttraumatic arthrosis of the ankle without infection. Solid and painless arthrodesis was achieved in all patients in 7–15 weeks, including those with an active infection or failed multiple previous operations. While the method is useful for primary treatment of ankle arthrosis, we think it is better for treatment of certain complicated cases.

Painful ankle arthrosis that is refractory to medical treatment is the commonest indication for arthrodesis of the ankle joint. Ilizarov and Okulov (1976) originally proposed a method for performing ankle arthrodesis which, however, did not gain much popularity and only a few reports on it have been published. Hawkins et al. (1994) performed ankle arthrodesis with the Ilizarov apparatus in 21 patients having complex distal tibial pathology or previous failed ankle arthrodesis. They obtained good results in 16 of their patients. Johnson et al. (1992) treated another 6 patients. Tibiotalar fusion occurred at an average of 7 months in 3 of 4 infected patients with previous failed ankle arthrodesis, while the 2 primary ankle fusions healed at an average of 3.5 months

We have prospectively analyzed the results of the Ilizarov method for ankle arthrodesis in our institution.

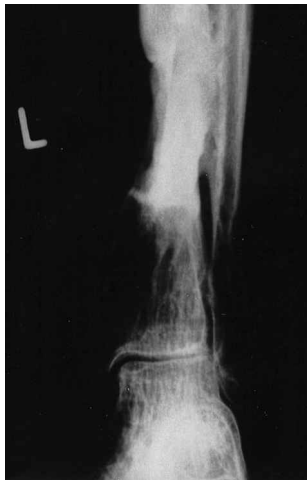Patients and methods

All 6 patients (4 men) who underwent tibiotalar arthrodesis by the Ilizarov method in our department during 1994–1998 were included in this study. They were under the care of MY who operated on them all. The average age was 52 (42–60) years. The average hospital stay was 10 (6–20) days, and they were followed in the outpatient clinic for an average of 36 (3–48) months (Table).

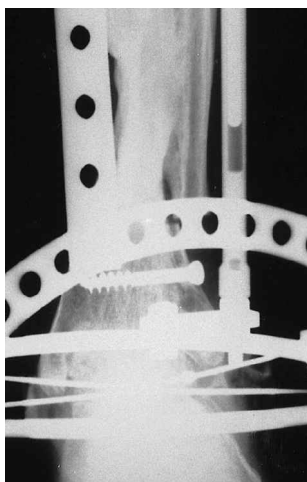
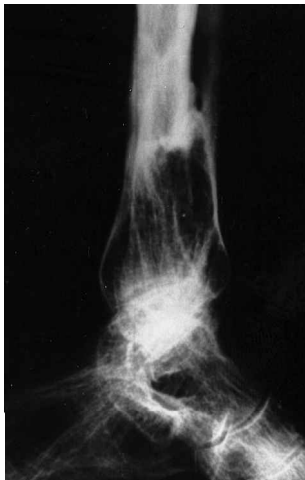3 patients had posttraumatic arthrosis of the ankle, following bimalleolar, trimalleolar or pilon fractures on average 12 (1–30) years before the arthrodesis. 2 of them had previously undergone surgery (internal fixation of the fracture, and the hardware had been removed in both) and 1 had been treated with a plaster cast. 1 patient had undergone open reduction and internal fixation of a distal tibial fracture and hardware removal 10 years earlier. This patient had chronic osteomyelitis of the distal tibia and severe arthrosis of the ankle, and had undergone several operations with debridement and drainage (Figure). 2 patients had undergone open reduction and internal fixation of open trimalleolar fractures of the ankle 2 months earlier, and the hardware had been removed. Both had active wound and joint infections.

Operative technique

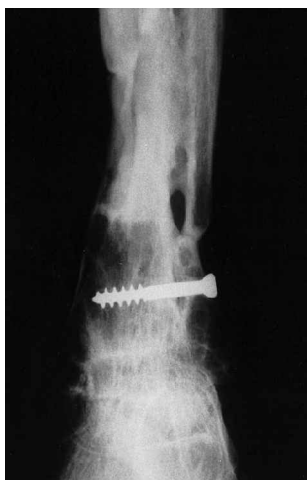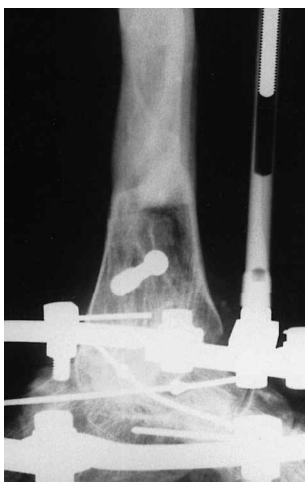
Arthrotomy was performed through a lateral incision and an oblique distal fibulotomy. Debridement of devitalized tissue and irrigation were performed when there was an infection. Articular cartilage was removed with an osteotome, with preservation of as much bone as possible. The



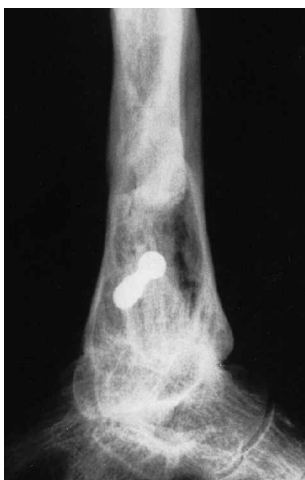A. Severe ankle arthrosis.



B. The Ilizarov apparatus in place.



C. 1-year postoperative radiographs show solid bony union.



talus was temporarily fixed to the distal tibia in a neutral position by Kirschner wires. Two circular frames were assembled and wires were inserted through the tibia and the talus and tightened to the frames. Longitudinal rods were attached to the frames to enable compression. The distal fibular fragment was fixed to the tibia by a screw.

To control equinus, a semicircular frame was attached to the circular frames with a wire going through the metatarsals (Figure). The wound was closed and the temporary wires were removed. The patients who had an infection received appropriate antibiotic treatment until it healed.

Compression was performed (1 mm daily) by the patient during the first 3 weeks after the operation. Weight bearing and physiotherapy were initiated as early as 2–3 days postoperatively. Control radiographs were taken every 2 weeks. The apparatus was removed after there was radiographic evidence of union and no movement in the arthrodesis site on clinical examination. The leg was placed in a protective short leg plaster cast for 4 weeks, during which full weight bearing was allowed.

Results

The Ilizarov apparatus was removed in the 3 infected patients after an average of 12 (10–15) weeks. 1 patient who had an open fracture needed skin grafting after necrosis of the wound margins had developed. The patients developed a superficial pin-tract infection that resolved after pin removal. They all had solid painless arthrodesis after cast removal (Figure) and could walk without crutches, one patient preferred to use a cane.

Patients who underwent Ilizarov ankle arthrodesis and results of follow-up

Case	Age	Gender	Diagnosis	Previous treatment	Time from original diagnosis	Infection	Time to bony union, weeks	Follow-up time, months	Results at follow-up
1	45	Female	Distal tibial fracture, chronic osteomyelitis, severe tibiotalar arthrosis	ORIF, hardware removal, multiple debridement procedures	10 years	Yes	10	44	Painless ankle; walks without support
2	42	Male	Pilon fracture, severe tibiotalar arthrosis	ORIF, hardware removal	1 year	No	9	36	Painless ankle; walks without support
3	53	Male	Bimalleolar ankle fracture, severe tibiotalar arthrosis	ORIF, hardware removal	5 years	No	8	46	Painless ankle; walks without support
4	60	Male	Trimalleolar ankle fracture, severe tibiotalar arthrosis	Closed reduction, plaster cast	30 years	No	7	44	Painless ankle; walks without support
5	60	Female	Open trimalleolar ankle fracture, wound and joint infection	ORIF, hardware removal, debridement	2 months	Yes	15	48	Painless ankle; uses a cane
6	50	Male	Open trimalleolar ankle fracture, wound and joint infection	ORIF, hardware removal, debridement	2 months	Yes	10	3	Painless ankle; walks without support

ORIF, open reduction and internal fixation

In the 3 patients with no infection, the apparatus was removed after an average of 8 (7–9) weeks. A superficial pin-tract infection developed in 2 patients and responded well to oral antibiotics. All had solid painless arthrodesis after the cast was removed and could walk without crutches.

No complications regarding use of the screw for fixation of the distal fibular fragment were observed, even in patients with an infection.

Discussion

Ankle joint arthrosis is usually caused by idiopathic arthrosis, rheumatoid arthritis or posttraumatic arthrosis. A few patients develop sequelae of septic arthritis or an ongoing chronic septic process. Patients with a previous failed arthrodesis are the most difficult to treat.

Ankle arthrodesis can be performed by various methods: conventional open arthrotomy with excision of the articular cartilage and fixation by screws or a plate (Mann and Rongstad 1998), arthroscopic approach with denuding of the articular cartilage and screw fixation (Cheng and Ferkel 1998), or external fixation and compression using

open or arthroscopic arthrotomy (Ilizarov and Okulov 1976). The first two methods are useful for patients with arthrosis of rheumatic, idiopathic or posttraumatic etiology, with the arthroscopic method being clearly superior in terms of the time of fusion and the rate of fusion (Corso and Zimmer 1995). We believe that for patients with an infection or a failed previous arthrodesis, external fixation may be the best choice.

According to our experience, Ilizarov’s method can be used to obtain a speedy, painless and solid ankle fusion in the most difficult cases, including patients with an active infection and those who have undergone multiple previous failed operations. The results are comparable to arthroscopic methods for primary arthrodesis (Corso and Zimmer 1995) and, although less comfortable for the patient who must walk with the bulky apparatus for many weeks, it may be used in hospitals where arthroscopy of the ankle is not available.

Cheng J C, Ferkel R D. The role of arthroscopy in ankle and subtalar degenerative joint disease. Clin Orthop 1998; 349: 65-72.

Corso S J, Zimmer T J. Technique and clinical evaluation of arthroscopic ankle arthrodesis. Arthroscopy 1995; 11: 585-90.

- Hawkins B J, Langerman R J, Anger D M, Calhoun J H. The Ilizarov technique in ankle fusion. *Clin Orthop* 1994; 303: 217-25.
- Ilizarov G A, Okulov G V. Compression arthrodesis of the ankle joint and adjacent foot joints. *Ortop Travmatol Protez* 1976; 11: 54-7.
- Johnson E E, Weltmer J, Lian G J, Gracchiolo A. III. Ilizarov ankle arthrodesis. *Clin Orthop* 1992; 280: 160-9.
- Mann R A, Rongstad K M. Arthrodesis of the ankle: a critical analysis. *Foot Ankle Int* 1998;19 (1):3-9.