

Taylor & Francis
Taylor & Francis Group

Acta Orthopaedica Scandinavica

ISSN: 0001-6470 (Print) (Online) Journal homepage: informahealthcare.com/journals/iort19

Large tumor endoprostheses and extracortical bone-bridging: 28 patients followed 10-20 years

Duk-Seop Shin, Peter F M Choong, Edmund Y H Chao & Franklin H Sim

To cite this article: Duk-Seop Shin, Peter F M Choong, Edmund Y H Chao & Franklin H Sim (2000) Large tumor endoprostheses and extracortical bone-bridging: 28 patients followed 10-20 years, Acta Orthopaedica Scandinavica, 71:3, 305-311, DOI: 10.1080/000164700317411933

To link to this article: https://doi.org/10.1080/000164700317411933

Published online: 08 Jul 2009.

Large tumor endoprostheses and extracortical bone-bridging

28 patients followed 10–20 years

Duk-Seop Shin[1], Peter F M Choong[2], Edmund Y H Chao[3] and Franklin H Sim[4]

Departments of Orthopaedics, [1]Yeungnam University Hospital, Taegu, Korea, [2]St. Vincent's Hospital, 41 Victoria Parade, Fitzroy 3065, Australia. Tel +61 3–9288 3980. Fax –9415 8677. E-mail: peterchoong@yahoo.com, [3]Johns Hopkins Hospital, Baltimore, Maryland, USA, [4]Mayo Clinic, Rochester, Minnesota, USA. Correspondence: Dr. P. Choong
Submitted 99-05-15. Accepted 99-12-27

ABSTRACT – Aseptic loosening is a common cause of failure in large tumor endoprostheses. The concept of extracortical bone-bridging was developed to tackle the problem of loosening. New bone which forms across the junction of the bone-prosthesis junction is believed to improve fixation by controlling the transfer of stresses across the junction as well as by giving additional stability to the prosthesis. We present the long-term experience with this concept following major reconstruction after tumor and non-tumor conditions in 31 patients.

The overall function was good for upper and lower limb prostheses. Most patients had extracortical bone bridging which was maintained for over 10 years. In 1/3 of patients this involved over 75% of the prosthetic circumference. Prosthetic survival was best with intercalary devices, followed by proximal femoral and distal femoral prostheses. Survival of prostheses in young active patients was similar to that reported in older patients undergoing primary joint replacement.

■

Large segmental prosthetic reconstruction of joints following tumor resection or revision joint surgery, and intercalated prosthetic reconstruction of diaphyseal defects following tumor resection share the substantial risk of aseptic implant loosening.

The design of many fixed and mobile segmental prostheses now includes a collar of porous coating around the shoulder of the prostheses adjacent to host diaphyseal bone. This facilitates the ingrowth into the prosthesis of bone graft that is placed to span the prosthesis-host junction. This so-called extracortical bone bridging has possible advantages, the most important of which include improved implant fixation and improved load transfer across the prosthesis-host junction (Chao and Sim 1992). We give the 10–20-year radiographic and functional results of prosthetic implants that utilize extracortical bone bridging to entrance fixation.

Material and methods

Patients

From 1976 to 1990, 59 patients at the Mayo Clinic underwent limb salvage surgery with segmental replacement prostheses that incorporated extracortical bone-bridging. Clinical, functional and radiographic information on all 31 patients were available for review. 28 patients (17 women) had more than 10 years' follow-up

The mean age was 36 (14–69) years. 26 patients underwent surgery for neoplastic conditions, while 5 had surgery for non-neoplastic conditions. The mean age of the tumor group was 31 years and that of the non-tumor group was 56 years.

Location

The femur was affected in 25 patients (proximal femur 10, diaphysis 3, distal femur 12), the tibia was affected in 4 cases (proximal tibia 1, tibial diaphysis 3), and the proximal humerus was involved in 2 patients.

Table 1. Distribution of prostheses by anatomical site of surgery

Anatomical site of resection	Patients n	Prosthesis type	Prostheses n
Distal femur	12	Knee arthrodesis prosthesis	7
		Total knee arthroplasty	5
Proximal femur	10	Total hip arthroplasty	10
Femoral diaphysis	3	Intercalary prosthesis	3
Tibial diaphysis	3	Intercalary prosthesis	3
Proximal humerus	2	Proximal humeral prosthesis	2
Proximal tibia	1	Knee arthrodesis prosthesis	1

Operations

There were 14 reconstructions following primary tumor resections, 12 revisions of prostheses implanted following previous resection of tumor, and 5 revisions of prostheses following non-tumor procedures (Table 1).

Of the 14 primary tumor cases, there were 6 osteosarcomas, 4 chondrosarcomas, 1 malignant fibrous histiocytoma, 1 adamantinoma, 1 giant cell tumor and 1 desmoplatic fibroma. The histology of resected tumors in which the original prostheses were revised included 4 osteosarcomas, 1 chondrosarcoma, 1 Ewing's tumor, 5 giant cell tumors and 1 case of Gorham's disease. The non-tumor cases comprised 3 revision arthroplasties for congenital hip dysplasia, 1 case of trauma and 1 case of rheumatoid arthritis.

In tumor patients, the tumor and surgical margins achieved were classified according to the criteria established by the Musculoskeletal Tumor Society (Enneking et al. 1980).

Prostheses

Because the patients in this retrospective review spanned 15 years, 2 types of porous-coated segmental implants were utilized. One system was based on a Co-Cr-Mo cast material with a beaded porous surface, and the other system employed Ti-6Al-4V alloy with pure titanium fibermetal porous coating (Chao and Sim 1992). Both systems contain porous coating at the prosthetic shoulder of the segmental portion of the prosthesis to enhance extracortical bone-bridging. Prosthetic components were used as a single or modular system, according to the condition of the resection site. We used bone cement for the prosthetic stem fixation, to provide secure initial fixation, except in 7 patients where we used a press-fit system. Titanium fiber metal-coated prostheses were used in 23 patients and cobalt-chrome-molybdenum implants with beaded porous coating were used in 8 patients.

In all cases, abundant autogenous iliac bone grafts (n 26) or a combination of autogenous iliac bone and banked allogenic bone (n 5) were applied at the bone-prosthesis junction.

Follow-up

Follow-up was calculated from the time of surgery to the last date of review or death. The series was updated by reviewing the clinical charts and roentgenograms. Radiographs of patients followed up elsewhere were also sent to our institution for review. In addition, a standardized questionnaire regarding clinical outcome and function was sent to every patient. Evaluation of disease status and functional results at last follow-up review was performed for all patients.

When information on all patients who had undergone surgery 10 years before were reviewed, 25 were alive, 4 had died (3 after 10 years, 1 at 3 years), and 2 patients had been lost to follow-up at 5.5 and 6.5 years. In the long-term assessment of survival (> 10 years), we excluded the 2 patients who were lost to follow-up and the patient who died at 3 years. The mean length of follow-up was 12.5 (10–20.2) years.

Functional assessment

Function was assessed by the modified function evaluation system recommended by Enneking at al (Enneking et al. 1993). With this system, functional assessment is based on an analysis of factors (pain, functional activities, and emotional acceptance) pertinent to the patient as a whole and factors specific to either the upper limb (positioning of hand, manual dexterity, and lifting ability) or the lower limb (use of external supports, walking ability, and gait). For each of 6 factors, values of 0–5 are assigned on the basis of established criteria. Descriptive terms like excellent, good, fair, or poor are not assigned to a specific numerical range, rather the result is expressed as the proportion of expected normal function for the patient.

Table 2. Mean functional outcome scores in 28 patients

Parameter	Tumor	Non-tumor	Hip	Knee	Femoral diaphysis	Tibial diaphysis	Humerus
Pain	3.6	4.2	3.4	3.5	4.0	5.0	5.0
Function	3.2	3.4	2.8	3.1	4.3	5.0	3.0
Emotional acceptance	3.4	4.8	4.1	2.8	5.0	5.0	3.0
External support	3.3	2.6	2.8	3.4	5.0	5.0	
Walking ability	3.4	4.2	3.6	3.7	4.3	5.0	
Gait	2.7	4.0	3.1	2.8	4.0	4.0	
Positioning of hand	2.0						2.0
Manual dexterity	5.0						5.0
Lifting ability	2.5						2.5
Overall functional rating, %	69	77	66	64	97	89	70

Maximum score for each parameter is 5

The full score of all functional categories is 30, so the rating percentile (%) is calculated on the basis of the perfect score of 30.

Radiographic assessment

Radiographic evaluation was performed according to the International Symposium on Limb Salvage radiological implant evaluation system (Glasser and Langlais 1991). In this system, 6 parameters are used to evaluate the results of segmental prostheses: bone remodeling, interface, anchorage, implant body problem, implant articulation, and extracortical bone bridging.

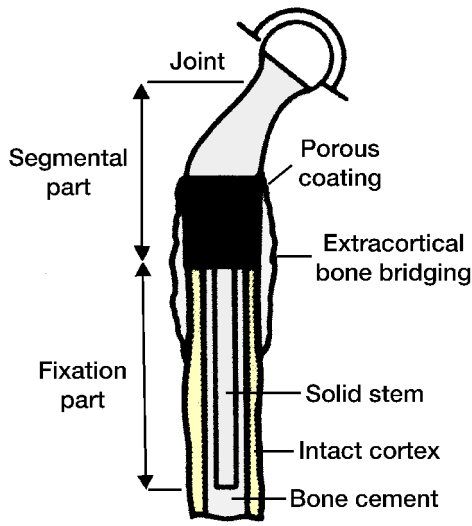

Figure 1. Schematic diagram indicating area of extracortical bone-bridging overlying bone prosthetic junction.

Prosthetic survival

Overall survival of the prostheses was estimated by Kaplan-Meier methods from the date of surgery to the date of prosthetic failure. Failure of device was defined as having any cause, except local recurrence, that required exchange of any component of the prosthesis, or revision.

Results

Functional assessment

The overall mean functional result of this study group was rated as 21 at a mean follow-up of 12 years (Table 2). The mean functional rating was 21 for the tumor group and 23 for the non-tumor group.

The mean functional score was best following reconstruction of the tibial diaphysis at a mean follow-up of 19 years, followed by the femoral diaphysis at 13 years. The functional rating for the proximal humerus, proximal femur and hip joint and the distal femur and knee joint were similar at 10, 12 and 12 years' follow-up, respectively (Table 2).

The functional score following revision of old implants from the non-tumor group was 23, followed by 22 in the group who underwent primary tumor resection and reconstruction, and 20 in those who underwent revision of an earlier implant from the tumor group.

Figure 2. Extracortical bone-bridging overlying bone prosthetic junction of a) proximal femoral prosthesis, and b)distal femoral prosthesis.

Figure 3. Extracortical bone-bridging ((a) anterior-posterior and b) lateral projections) overlying porous-coated shaft of intercalary device.

Table 3. Radiographic results of extracortical bone bridging in 26 patients

Parameters	Excellent	Good	Fair	Poor
Bone remodeling	13	10	1	2
Interface	14	9	3	0
Anchorage	22	2	1	1
Implant body	22	2	0	2
Implant articulation	19	2	2	3
Bone bridging	9	13	2	2

Radiographic assessment

Radiographs were available for assessment in 26 of the 28 patients (Table 3).

Bone remodeling. 13 patients showed no change in bone remodeling compared to the discharge roentgenogram. 10 had either osteopenia or hypertrophic changes, 1 had resorption of the fixation area, with 40% loss of cortical thickness and 1.5 cm in length, 1 had nearly complete bone loss in the proximal femur, and 1 had developed a femoral shaft fracture.

Interface. 14 patients showed no radiolucent lines. 9 patients had incomplete radiolucent lines less than 2 mm in thickness. 3 patients had radiolucent lines more than 2 mm in thickness, but not completely around the stem.

Stem anchorage. Most patients were evaluated as excellent, with no change from their discharge radiograph.

Implant body problems. There were 2 prosthetic fractures, which were scored as poor, and all others were ranked as excellent or good.

Implant articulation. 21 implants were radiographically evaluated as excellent or good.

Extracortical bone bridging. 9 patients had bone bridging over more than 75% of the entire circumference of the porous-coated area, with no radiolucent lines, 13 had 50–75%, 2 had 25–50%, and 2 had less than 25% bone bridging and showed cortical resorption. Additional bone grafting was performed in three patients who had insufficient extracortical bone bridging.

Clinical outcome

5 total prosthetic revisions were required for the 3 prosthetic failures and 2 prosthetic fractures, while a vascularized fibular graft was used to treat

a third case of prosthesis fracture. These were performed an average of 6 (0.7–11) years after implantation.

6 cases of aseptic loosening were treated with acetabular component revision in 3 cases, while 2 tibial components and 1 femoral component were revised in 3 knee arthrodesis prostheses. Loosening of a humeral prosthesis was treated with revision reimplantation. These revisions were performed omm the average 5 (1.2–13) years after implantation.

Finally, of the 2 infected prostheses, 1 was treated with a vascularized fibular graft, following removal of the infected prosthesis, and the other underwent an above-knee amputation due to deep infection at 9 years after operation for a failed total hip arthroplasty for rheumatoid arthritis.

Prosthetic survival in the entire group was 75% (SD 8) at 5 years, 68% ± 8 at 10 years, and 46% (13) at 15 years. The prosthetic survival in the tumor group was 73% (8) at 5 years, 69% (8) at 10 years and 49% (13) at 15 years, and in the non-tumor group it was 80% (16), 60% (19) and 30% (17), respectively, but there was no significant difference between the 2 groups.

The prosthetic survival following diaphyseal reconstruction was 83% (SD 14) at 15 years and following hip and proximal femoral reconstruction was 80% (11) at 5 years and 48% (17) at 10 years. Following knee and distal femoral reconstruction, it was 77% (10) at 5 years, 60% (12) at 10 years and 48% ± 15 at 15 years.

Discussion

Design concepts that aim to improve the fixation of prostheses to bone are important for extending the longevity of large segmental endoprostheses, which by their nature and use are prone to early failure. Extracortical bone bridging (EBB) is a technique that seeks to encourage bone growth to span the junction between the extracortical surface of bone and the adjacent porous-coated shoulder of a prosthesis (Chao and Sim 1992). The theoretical advantages of successful EBB include enhanced implant fixation, a gradual transfer of stresses across the bone prosthesis junction, and improved support of the stem-body portion of the prosthesis (Virolainen et al. 1999). A further advantage is believed to include a reduction in the passage of micro-particles from the joint milieu to the cement/bone interface by formation of a so-called purse string of bony or fibrous tissue at the junction between diaphyseal bone and the shoulder of the prosthesis (Virolainen et al. 1999).

Our experience with EBB has included a variety of implants, most of which have been used following tumor resection (Kohles et al. 1994, Malkani et al. 1995, Sim et al. 1995, Choong et al. 1996). Our current experience with patients who were followed up for more than 10 years suggests that large segmental endoprostheses of the knee, hip and diaphyses of long bones should be seriously considered for young tumor patients, and for those who undergo revision of failed joint replacements, who may also be candidates for biologic reconstructions with allograft material. The work of Virolainen et al. (1999) provides support for a mechanical role of extracortical bone bridging in prosthetic fixation and this may account, in part, for the good long-term results observed. Despite the size of the bony and soft tissue resection, overall function was good at 12 years. As expected, however, there was a decline in the functional score between 5 and 10 years, which represents the anticipated implant failures that occurs with most prostheses over time.

We observed better function in patients treated for non-tumor conditions than those treated for tumor conditions, and this is most likely due to the need for more extensive soft tissue resection in the latter cases. For a similar reason, revision arthroplasty in tumor patients gave a poorer function than in non-tumor patients.

While the reports on the use of prosthetic diaphyseal replacements are few (Abudu et al. 1996, Damron et al. 1996), the outcome is favorable like that reported from the more extensive experience with allografts (Mankin et al. 1987, Kattapuram et al. 1989, Muscolo et al. 1992, Donati et al. 1993, Cara et al. 1994, Voggenreiter et al. 1995). Our results, which represent the longest follow-up to date, show promising longevity and function after prosthetic reconstruction of diaphyseal defects. Possible explanations of this may include the presence of mobile joints on either side of the prosthetic construct, which would theoretically

dissipate the forces that are transmitted across the intercalary prosthesis. Second, the availability of EBB may enhance fixation of the intercalary device in a manner similar to the union of host to allograft bone. Prosthetic diaphyseal reconstruction may be a reliable alternative to biologic reconstruction when the complications of the use of allografts are considered (Lord et al. 1988, Tomford et al. 1990, Dick and Strauch 1994).

In general, the survivals of the various joint implants were similar. This was an interesting finding because of the relative youth of our patients, who would be expected to have a greater predisposition to prosthetic loosening than older patients (White 1988, Sarmiento et al. 1990, Stromberg and Herberts 1996).

Radiographic loosening was uncommon in our patients, with only 2 patients showing evidence of periprosthetic lucent lines larger than 2 mm. This finding is given in the context where EBB involving mor than 25% of the circumference of the host-prosthetic junction was observed in 24 of the 26 patients and where most patients had over 50% EBB. It is reassuring that substantial EBB was present and maintained, even over a decade after implantation. Despite this, it is important to note that in 2 cases not only was there less than 25% EBB but resorption was also present. While the reasons for this are unclear, the placement of sufficient graft around the entire circumference of the shoulder of the prosthesis at the host-prosthesis interface may be important for the development of substantial EBB.

The protagonists of biologic reconstructions for large segmental defects following tumor resection have highlighted the risk of early failure from loosening of prosthetic implants. Our study has shown that tumor endoprostheses may have a valuable role in limb-sparing surgery, with good preservation of function and commensurate prosthetic survival in the first decade. We recognize the limitations of a retrospective study, such as ours and accept that our results do not allow us to conclude that EBB is directly responsible for extended longevity of the megaprostheses used. However, we are encouraged by the fact that extracortical bone bridging, which occurs after bone grafting of osteotomies, also appears to be active at host-prosthetic junctions even after 10 years. This lends support to the thesis that the strength of fixation at the bone-prosthesis interface may be enhanced by EBB.

Abudu A, Carter S R, Grimer R J. The outcome and functional results of diaphyseal endoprostheses after tumour excision. J Bone Joint Surg (Br) 1996; 78: 652-7.

Cara J A, Lacleriga A, Canadell J. Intercalary bone allografts. 23 tumor cases followed for 3 years. Acta Orthop Scand 1994; 65: 42-6.

Chao E Y, Sim F H. Composite fixation of salvage prostheses for the hip and knee. Clin Orthop 1992; 276: 91-101.

Choong P F M, Sim F H, Pritchard D J, et al. Megaprostheses after resection of distal femoral tumors. Acta Orthop Scand 1996; 67: 345-51.

Damron T A, Sim F H, Shives T C, et al. Intercalary spacers in the treatment of segmentally-destructive diaphyseal humeral lesions in disseminated malignancies. Clin Orthop 1996; 324: 233-43.

Dick H M, Strauch R J. Infection of massive bone allografts. Clin Orthop 1994; 306: 46-53.

Donati D, Capanna R, Campanacci D, et al. The use of massive bone allografts for intercalary reconstruction and arthrodeses after tumor resection. A multicentric European study. Chir Organi Mov 1993; 78: 81-94.

Enneking W F, Spanier S S, Goodman M A. A system for the surgical staging of musculoskeletal sarcoma. Clin Orthop 1980; 153: 106-20.

Enneking WF, Dunham W, Gebhardt M C, et al. A system for the functional evaluation of reconstructive procedures after surgical treatment of tumors of the musculoskeletal system. Clin Orthop 1993; 286: 241-6.

Glasser D, Langlais F. The ISOLS radiological implants evaluation system. In: Limb salvage. Major reconstructions in oncologic and nontumoral conditions (Eds. Langlais F, Tomeno B). Springer-Verlag, Berlin 1991: xxiii-xxxi.

Kattapuram S V, Phillips W C, Mankin H J. Intercalary bone allografts: radiographic evaluation. Radiology 1989; 170: 137-41.

Kohles S S, Markel M D, Rock M G, et al. Mechanical evaluation of six types of reconstruction following 25, 50, and 75% resection of the proximal femur. J Orthop Res 1994; 12: 834-43.

Lord C F, Gebhardt M C, Tomford W W, Mankin H J. Infection in bone allografts. Incidence, nature, and treatment. J Bone Joint Surg (Am) 1988; 70: 369-76.

Malkani A L, Settecerri J J, Sim F H, et al. Long-term results of proximal femoral replacement for non-neoplastic disorders. J Bone Joint Surg (Br) 1995; 77: 351-6.

Mankin H J, Gebhardt M C, Tomford W W. The use of frozen cadaveric allografts in the management of patients with bone tumors of the extremities. Orthop Clin North Am 1987; 18: 275-89.

Muscolo D L, Petracchi L J, Ayerza M A, Calabrese M E. Massive femoral allografts followed for 22 to 36 years. Report of six cases. J Bone Joint Surg (Br) 1992; 74: 887-92.

Sarmiento A, Ebramzadeh E, Gogan W J, McKellop H A. Total hip arthroplasty with cement. A long-term radiographic analysis in patients who are older than fifty and younger than fifty years. J Bone Joint Surg (Am) 1990; 72: 1470-6.

Sim F H, Frassica F J, Chao E Y. Orthopaedic management using new devices and prostheses. Clin Orthop 1995; 312: 160-72.

Stromberg C N, Herberts P. Cemented revision total hip arthroplasties in patients younger than 55 years old. A multicenter evaluation of second-generation cementing technique. J Arthroplasty 1996; 11: 489-99.

Tomford W W, Thongphasuk J, Mankin H J, Ferraro M J. Frozen musculoskeletal allografts. A study of the clinical incidence and causes of infection associated with their use. J Bone Joint Surg (Am) 1990; 72: 1137-43.

Virolainen P, Inoue N, Nagao M, et al. Autogenous onlay grafting for enhancement of extracortical tissue formation over porous-coated segmental replacement prostheses. J Bone Joint Surg (Am) 1999; 81: 493-9.

Voggenreiter G, Klaes W, Assenmacher S, Schmit-Neuerburg K P. Massive intercalary bone allografts in the treatment of primary and secondary bone tumors. A report on 21 cases. Arch Orthop Trauma Surg 1995; 114: 308-18.

White S H. The fate of cemented total hip arthroplasty in young patients. Clin Orthop 1988; 231: 29-34.