The Journal of Maternal-Fetal & Neonatal Medicine

ISSN: (Print) (Online) Journal homepage: informahealthcare.com/journals/ijmf20

A mitochondrial regulator protein, MNRR1, is elevated in the maternal blood of women with preeclampsia

Manaphat Suksai, Roberto Romero, Mariachiara Bosco, Francesca Gotsch, Eunjung Jung, Piya Chaemsaithong, Adi L. Tarca, Dereje W. Gudicha, Nardhy Gomez-Lopez, Marcia Arenas-Hernandez, Arun Meyyazhagan, Lawrence I. Grossman, Siddhesh Aras & Tinnakorn Chaiworapongsa

To cite this article: Manaphat Suksai, Roberto Romero, Mariachiara Bosco, Francesca Gotsch, Eunjung Jung, Piya Chaemsaithong, Adi L. Tarca, Dereje W. Gudicha, Nardhy Gomez-Lopez, Marcia Arenas-Hernandez, Arun Meyyazhagan, Lawrence I. Grossman, Siddhesh Aras & Tinnakorn Chaiworapongsa (2024) A mitochondrial regulator protein, MNRR1, is elevated in the maternal blood of women with preeclampsia, The Journal of Maternal-Fetal & Neonatal Medicine, 37:1, 2297158, DOI: 10.1080/14767058.2023.2297158

To link to this article: https://doi.org/10.1080/14767058.2023.2297158

THE JOURNAL OF MATERNAL-FETAL & NEONATAL MEDICINE
2023, VOL. 37, NO. 1, 2297158
https://doi.org/10.1080/14767058.2023.2297158

Taylor & Francis
Taylor & Francis Group

ORIGINAL ARTICLE

A mitochondrial regulator protein, MNRR1, is elevated in the maternal blood of women with preeclampsia

Manaphat Suksai[a,b,c], Roberto Romero[a,d,e], Mariachiara Bosco[a,b,f], Francesca Gotsch[a,b], Eunjung Jung[a,b,g], Piya Chaemsaithong[a,b,h], Adi L. Tarca[a,b,i,j], Dereje W. Gudicha[a,b], Nardhy Gomez-Lopez[a,b,j,k*], Marcia Arenas-Hernandez[a,b], Arun Meyyazhagan[a,b,l], Lawrence I. Grossman[a,j], Siddhesh Aras[a,j] and Tinnakorn Chaiworapongsa[a,b]

[a]Pregnancy Research Branch, Division of Obstetrics and Maternal-Fetal Medicine, Division of Intramural Research, *Eunice Kennedy Shriver* National Institute of Child Health and Human Development, National Institutes of Health, United States Department of Health and Human Services, Bethesda, MD, USA; [b]Department of Obstetrics and Gynecology, Wayne State University School of Medicine, Detroit, MI, USA; [c]Department of Obstetrics and Gynecology, Faculty of Medicine, Prince of Songkla University, Songkhla, Thailand; [d]Department of Obstetrics and Gynecology, University of Michigan, Ann Arbor, MI, USA; [e]Department of Epidemiology and Biostatistics, Michigan State University, East Lansing, MI, USA; [f]Department of Obstetrics and Gynecology, AOUI Verona, University of Verona, Verona, Italy; [g]Department of Obstetrics and Gynecology, Busan Paik Hospital, Inje University College of Medicine, Busan, Republic of Korea; [h]Department of Obstetrics and Gynecology, Faculty of Medicine, Ramathibodi Hospital, Mahidol University, Bangkok, Thailand; [i]Department of Computer Science, Wayne State University College of Engineering, Detroit, MI, USA; [j]Center for Molecular Medicine and Genetics, Wayne State University, Detroit, MI, USA; [k]Department of Biochemistry, Microbiology and Immunology, Wayne State University School of Medicine, Detroit, MI, USA; [l]Centre of Perinatal and Reproductive Medicine, University of Perugia, Perugia, Italy

ABSTRACT

Objective: Preeclampsia, one of the most serious obstetric complications, is a heterogenous disorder resulting from different pathologic processes. However, placental oxidative stress and an anti-angiogenic state play a crucial role. Mitochondria are a major source of cellular reactive oxygen species. Abnormalities in mitochondrial structures, proteins, and functions have been observed in the placentae of patients with preeclampsia, thus mitochondrial dysfunction has been implicated in the mechanism of the disease. Mitochondrial nuclear retrograde regulator 1 (MNRR1) is a newly characterized bi-organellar protein with pleiotropic functions. In the mitochondria, this protein regulates cytochrome *c* oxidase activity and reactive oxygen species production, whereas in the nucleus, it regulates the transcription of a number of genes including response to tissue hypoxia and inflammatory signals. Since MNRR1 expression changes in response to hypoxia and to an inflammatory signal, MNRR1 could be a part of mitochondrial dysfunction and involved in the pathologic process of preeclampsia. This study aimed to determine whether the plasma MNRR1 concentration of women with preeclampsia differed from that of normal pregnant women.

Methods: This retrospective case–control study included 97 women with preeclampsia, stratified by gestational age at delivery into early (<34 weeks, $n=40$) and late (≥34 weeks, $n=57$) preeclampsia and by the presence or absence of placental lesions consistent with maternal vascular malperfusion (MVM), the histologic counterpart of an anti-angiogenic state. Women with an uncomplicated pregnancy at various gestational ages who delivered at term served as controls ($n=80$) and were further stratified into early ($n=25$) and late ($n=55$) controls according to gestational age at venipuncture. Maternal plasma MNRR1 concentrations were determined by an enzyme-linked immunosorbent assay.

Results: 1) Women with preeclampsia at the time of diagnosis (either early or late disease) had a significantly higher median (interquartile range, IQR) plasma MNRR1 concentration than the controls [early preeclampsia: 1632 (924–2926) pg/mL vs. 630 (448–4002) pg/mL, $p=.026$, and late preeclampsia: 1833 (1441–5534) pg/mL vs. 910 (526–6178) pg/mL, $p=.021$]. Among women with early preeclampsia, those with MVM lesions in the placenta had the highest median (IQR) plasma MNRR1 concentration among the three groups [with MVM: 2066 (1070–3188) pg/mL vs. without MVM: 888 (812–1781) pg/mL, $p=.03$; and with MVM vs. control: 630 (448–4002) pg/mL, $p=.04$]. There was no significant difference in the median plasma MNRR1 concentration between women

ARTICLE HISTORY
Received 29 June 2023
Revised 12 December 2023
Accepted 15 December 2023

KEYWORDS
CHCHD2; early preeclampsia; intravascular inflammation; late preeclampsia; maternal vascular malperfusion; oxidative stress; placenta; pregnancy

CONTACT Roberto Romero, romeror@mail.nih.gov Pregnancy Research Branch, Division of Obstetrics and Maternal-Fetal Medicine, Division of Intramural Research, *Eunice Kennedy Shriver* National Institute of Child Health and Human Development, National Institutes of Health, United States Department of Health and Human Services, Bethesda, MD, USA

The study was conducted at the Perinatology Research Branch, NICHD/NIH/DHHS, in Detroit, Michigan; the Branch has since been renamed as the Pregnancy Research Branch, NICHD/NIH/DHHS.

*Present Affiliation: Departments of Obstetrics and Gynecology & Pathology and Immunology, Washington University School of Medicine, St Louis, MO, USA

with early preeclampsia without MVM lesions and those with an uncomplicated pregnancy ($p = .3$). By contrast, women with late preeclampsia, regardless of MVM lesions, had a significantly higher median (IQR) plasma MNRR1 concentration than women in the control group [with MVM: 1609 (1392–3135) pg/mL vs. control: 910 (526–6178), $p = .045$; and without MVM: 2023 (1578–8936) pg/mL vs. control, $p = .01$].

Conclusions: MNRR1, a mitochondrial regulator protein, is elevated in the maternal plasma of women with preeclampsia (both early and late) at the time of diagnosis. These findings may reflect some degree of mitochondrial dysfunction, intravascular inflammation, or other unknown pathologic processes that characterize this obstetrical syndrome.

Introduction

Preeclampsia, an obstetrical syndrome [1] characterized by hypertension accompanied by either proteinuria or signs of systemic involvement [2,3], is a leading cause of maternal death and indicated preterm birth [4–6]. This condition is a heterogenous disorder [7] resulting from different pathologic processes [7–40]. Uterine ischemia leading to placental oxidative stress [22,41–51] is thought to be the principal mechanism of disease [52–59]. Stressed trophoblasts then release products, such as anti-angiogenic factors, pro-inflammatory cytokines, trophoblast debris, and extracellular vesicles, among others [60], into the maternal circulation causing systemic intravascular inflammation, endothelial dysfunction [46,47], and multi-organ damage [8,10,61–64]. Due to the differences in the clinical presentation and frequency of adverse perinatal outcomes, preeclampsia has been classified into early (<34 weeks) and late (≥34 weeks) disease according to the gestational age at diagnosis or at delivery [65,66]. Subsequently, experts recognized that disaggregation of preeclampsia by gestational age alone does not capture the complexity of this syndrome and its clinical needs [66]. Recently, the presence of placental lesions of maternal vascular malperfusion (MVM) [67], the histologic counterpart of the anti-angiogenic stage, has been proposed to be of use in the development of a new taxonomy of obstetrical syndromes, including preeclampsia [68]. A sub-classification of preeclampsia according to placental pathologic findings or concentrations of angiogenic/anti-angiogenic factors in maternal blood, which reflect the mechanisms of disease, may facilitate the discovery and implementation of biomarkers to improve the prediction and prevention of preeclampsia [68,69].

Mitochondria are intracellular organelles responsible for the generation of adenosine triphosphate (ATP) for cellular energy [70,71], and they also represent the main source of reactive oxygen species (ROS) [72,73]. Indeed, several studies observed abnormalities in the mitochondrial structures, proteins, and functions in the placentae of patients with preeclampsia. Thus, mitochondrial dysfunction, in this case, defined as an inability to control excessive ROS generation, has been implicated in the mechanisms of disease leading to preeclampsia. Mitochondrial nuclear retrograde regulator 1 (MNRR1), also known as Coiled-Coil-Helix-Coiled-Coil-Helix Domain-Containing Protein 2 (CHCHD2), is a newly characterized bi-organellar protein with pleiotropic functions. In the mitochondria, this protein regulates cytochrome *c* oxidase (COX) activity, the rate-limiting enzyme of mitochondrial respiration [74–76]. Reduced cellular levels of MNRR1 can lead to a reduction in oxygen consumption and an increase in ROS production [74]. In response to tissue hypoxia, MNRR1 accumulates in the nucleus where it is a transcriptional activator of itself and other genes involved in the cellular response to hypoxia [74,77].

Recently, our group reported that lipopolysaccharide, a bacterial endotoxin, can lower MNRR1 expression in trophoblast cells and that these changes are associated with mitochondrial dysfunction [78]. Since MNRR1 expression changes in response to hypoxia and inflammatory signals, MNRR1 could indicate mitochondrial dysfunction and could be involved in the pathogenesis of preeclampsia. Moreover, the concentration of MNRR1 in the maternal blood of women diagnosed with preeclampsia has not yet been examined. This study aimed to determine whether the plasma concentration of MNRR1 in women with preeclampsia differed from that of normal pregnant women. The preeclampsia group was stratified by gestational age at delivery into early or late disease and by the presence or absence of MVM lesions in the placenta.

Materials and methods

Study design and population

This case–control study was conducted by searching the clinical database and bank of biological samples of Wayne State University, the Detroit Medical Center, and the Perinatology Research Branch, NICHD/NIH/DHHS, and included women diagnosed with preeclampsia ($n = 97$: 40 early and 57 late disease) and

uncomplicated pregnant women in the control group ($n=80$). Women with preeclampsia had a blood sample collected at the time of diagnosis, whereas those in the control group had a blood sample collected at different gestational-age intervals after 20 weeks of gestation and delivered at term. Each patient contributed one maternal blood sample only. All patients with preeclampsia had a placental histologic examination. Patients with a multiple pregnancy or a fetus with congenital and/or chromosomal anomalies were excluded from the study.

All women provided written informed consent prior to the collection of maternal blood samples. The Institutional Review Boards of the NICHD and Wayne State University approved the collection and utilization of samples for research purposes. Many of these samples had been used in past studies that examined candidate biomarkers for preeclampsia.

Clinical definitions

Preeclampsia was defined as new-onset hypertension developing after 20 weeks of gestation (systolic and/or diastolic blood pressure of 140 mmHg and/or 90 mmHg) and proteinuria (300 mg in a 24-h urine collection, or two random urine specimens obtained 4 h to 1 week apart containing ≥1+ protein by dipstick) [79]. Superimposed preeclampsia was diagnosed if pregnant women with hypertension before 20 weeks of gestation developed new-onset proteinuria or a sudden increase in proteinuria or in blood pressure from their individual baselines [79]. Pregnant women who had severely high blood pressure levels (systolic ≥160 mmHg or diastolic ≥110 mmHg) or clinical symptoms (i.e. headache, visual disturbances, epigastric pain), or who developed thrombocytopenia (platelet count $<100\times10^9$/L), elevated liver enzymes (alanine aminotransferase or aspartate aminotransferase ≥70 IU/L), renal dysfunction (creatinine >1.1 mg/dL), or pulmonary edema, were classified as having preeclampsia with severe features [3]. Women with preeclampsia were stratified into early (<34 weeks of gestation) or late (≥34 weeks of gestation) disease according to the gestational age at delivery. Each group was further subdivided into those with and without placental lesions of MVM.

The control group was defined as women who had an uncomplicated pregnancy and met the following conditions: 1) no medical, obstetrical, or surgical complications; 2) not in labor; and 3) delivery of a term neonate (≥37 weeks of gestation) with a birthweight appropriate for gestational age (between the 10th and 90th percentiles) [80]. Like women with preeclampsia, women in the control group were stratified into early ($n=25$) and late disease ($n=55$) according to gestational age at venipuncture (<34 weeks or ≥34 weeks of gestation, respectively).

Sample collection and determination of human MNRR1 concentration in maternal plasma

Maternal blood samples were obtained by venipuncture and collected in EDTA (ethylenediaminetetraacetic acid)-containing tubes. The samples were centrifuged at 1300 X g for 10 min shortly after collection and stored at −80 °C until analysis. The MNRR1 concentrations in the plasma samples were determined by a commercially available immunoassay (Human MNRR1 ELISA Kit, Abbexa LTD, Cambridge, UK). Briefly, 100 µL of maternal plasma or calibrator were dispensed into separate wells of the assay plates and incubated for 90 min at 37 °C. After removal of the remaining sample and calibrator, the plates were washed twice with 1X wash buffer and 100 µL of detection reagent. A working solution was added to each well. Plates were then incubated for 60 min at 37 °C. Next, the plates were washed three times with 1X wash buffer, 100 µL of detection reagent B working solution were added to each well, and the plates were then incubated for 30 min at 37 °C. Subsequently, the plates were washed five times with 1X wash buffer and 90 µL of TMB substrate were added to each well. Plates were then mixed thoroughly and incubated for 20 min at 37 °C. Finally, 50 µL of stop solution were added into each well to halt the reaction. SpectraMax iD5 (Molecular Devices, San Jose, CA, USA) was used to read the plates and MNRR1 concentrations were calculated with SoftMax Pro 7 (Molecular Devices). The inter- and intra-assay coefficients of variation were 8.3% and 7.1%, respectively, with an assay sensitivity of 12.3 pg/mL.

Placental histologic examination

Sampling of the placentae was performed according to standardized protocols of the Perinatology Research Branch, as previously described [81]. Placental lesions consistent with MVM were diagnosed according to the criteria established by the Perinatology Section of the Society for Pediatric Pathology [82] and the Amsterdam Placental Workshop Group Consensus [83]. These criteria include the presence of at least one of the following: (1) villous changes, which can be categorized into abrupt onset (remote and recent villous infarcts), gradual onset with intermediate duration (increased syncytial knots, villous agglutination, increased intervillous fibrin), or gradual onset with prolonged duration (distal villous hypoplasia),

and (2) vascular lesions (persistent muscularization of the basal plate arteries, mural hypertrophy of the decidual arterioles, and acute atherosis of the basal plate arteries and/or of the decidual arterioles).

Statistical analysis

Demographic categorical data were summarized as proportions. The distribution of continuous data was assessed by a Kolmogorov–Smirnov test and visual plot inspection. Continuous data were summarized by medians and interquartile ranges (IQR). Differences between groups were examined by using a chi-square or a Fisher's exact test for categorical data and a Kruskal–Wallis or Mann–Whitney *U* test for continuous data. Quantile regression was applied to assess the differences in MNRR1 concentration between groups while adjusting for the effect of possible confounders (i.e. gestational age at venipuncture, duration of sample storage, and nulliparity). Spearman's correlation was used to assess the relationship between two continuous variables. A two-tailed *p* value of <.05 was considered statistically significant. The statistical package was SPSS v.19.0 (IBM Corporation, Armonk, NY, USA). Quantile regression was conducted by using the package *quantreg* from CRAN: http://cran.r-project.org available for R statistical language and environment (www.r-project.org).

Results

Characteristics of the study population

Demographics and clinical characteristics of pregnant women with preeclampsia and controls are reported in Table 1. Nulliparity was significantly more frequent among women with late preeclampsia compared to the controls [42.1% (24/57) vs. 7.3% (4/55); $p<.001$].

Table 2 displays the severity features of preeclampsia according to early or late disease. Severe features were present in 95% (38/40) and 86% (49/57) of women in the early and late preeclampsia groups, respectively. Even though the frequency of clinical symptoms (i.e. headache, visual disturbances, and epigastric pain) was not significantly different between the two groups, women diagnosed with early preeclampsia had higher systolic blood pressure levels [175 (167–188) mmHg vs. 162 (155–175) mmHg; $p=.007$] and higher concentrations of liver enzymes than those with late preeclampsia (Table 2). Moreover, MVM lesions were more frequently observed in the placentae of women with early compared to late preeclampsia [73% (29/40) vs. 42% (24/57); $p=.003$; Table 2].

Plasma MNRR1 concentration in women with preeclampsia

The median (IQR) plasma concentrations of MNRR1 in early and late preeclampsia were 2.6- and 2-fold higher, respectively, than those in the controls at the same gestational age range [early preeclampsia 1632 (924–2926) pg/mL vs. early control 630 (448–4002) pg/mL; $p=.03$, and late preeclampsia 1833 (1441–5534) pg/mL vs. late control 910 (526–6178) pg/mL; $p=.001$]. These differences remained significant after adjusting for potential confounders (gestational age at venipuncture and duration of sample storage for early preeclampsia: $p=.026$; gestational age at venipuncture and nulliparity for late preeclampsia: $p=.02$; Figure 1).

Plasma MNRR1 concentration in women with preeclampsia stratified by the presence or absence of placental lesions of MVM

Among women with early preeclampsia, those with MVM lesions had the highest median (IQR) plasma concentration of MNRR1 among the three groups [with MVM 2066 (1070–3188) pg/mL vs. without MVM

Table 1. Demographics and clinical characteristics of the study population.

	Early controls ($n=25$)	Early preeclampsia ($n=40$)	*p*	Late controls ($n=55$)	Late preeclampsia ($n=57$)	*p*
Maternal age (y)	24 (20.5–28)	25 (20.3–30.8)	0.4	22 (20–26)	23 (19.5–26)	.8
African American	88% (22)	77.5% (31)	0.3	92.7% (51)	89.5% (51)	.5
Nulliparity	24% (6)	27.5% (11)	0.8	7.3% (4)	42.1% (24)	<.001
Tobacco use	8% (2)	20% (8)	0.2	14.5% (8)	10.5% (6)	.5
Pre-pregnancy BMI (kg/m^2)	27.2 (23.5–35.6)	27.8 (22.7–32.3)[a]	0.7	28.3 (23.3–35.5)[b]	27.5 (23.7–32.7)[c]	.6
GA at venipuncture (weeks)	28.1 (25.8–30.7)	30.7 (27.6–32.7)	0.052	39.1 (38.7–39.3)	37.9 (35.9–39.3)	.002
GA at delivery (weeks)	39.1 (38.8–39.8)	31.3 (28.4–33.4)	<0.001	39.1 (39.0–39.6)	37.9 (36.2–39.4)	<.001
Birth weight (g)	3235 (3162.5–3395)	1297 (848.5–1678.8)	<0.001	3325 (3155–3510)	2705 (2202.5–3132.5)	<.001
Birthweight percentile	41.5 (31.1–54.1)	14.1 (6.9–23.1)	<0.001	44.9 (32.8–59.4)	22 (3.3–38.2)	<.001
Duration of sample storage (years)	13.3 (12.3–13.5)	15.1 (13.9–16.4)	<0.001	13.3 (12.2–13.9)	13.5 (12.5–14.2)	.1

BMI: body mass index; GA: gestational age.
Data are presented as median (interquartile range) or percentage (number of patients).
Mann–Whitney *U*-tests were used for continuous variables and Chi-square tests for categorical variables.
[a]$n = 36$; [b]$n = 53$; [c]$n = 55$.

Table 2. Severity features of pregnant women with early and late preeclampsia.

	Early preeclampsia ($n=40$)	Late preeclampsia ($n=57$)	p
Severe features	95% (38)	86% (49)	.2
Highest systolic blood pressure (mmHg)	175 (167.3–188)	162 (155–175)	.007
Highest diastolic blood pressure (mmHg)	108 (100–114.5)	103 (95.5–112)	.2
Systolic blood pressure ≥160 or diastolic blood pressure ≥110 mmHg	80% (32)	70.2% (40)	.3
Headache	42.5% (17)	42.1% (24)	.9
Visual disturbances	22.5% (9)	19.3% (11)	.7
Epigastric pain	15% (6)	12.3% (7)	.7
Highest serum AST (IU/L)	41 (26.3–89.8)	28 (21.3–33.8)[a]	<.001
Highest serum ALT (IU/L)	28 (21.8–67.8)[b]	19 (13.5–25)[c]	<.001
Elevated liver enzymes (AST or ALT ≥70 IU/L)	35% (14)	3.6% (2)[a]	<.001
Highest serum creatinine (mg/dL)	0.8 (0.6–0.9)[d]	0.7 (0.6–0.8)[e]	.2
Renal insufficiency (serum creatinine >1.1 mg/dL)	7.7% (3)[d]	2% (1)[e]	.2
Lowest platelet count (x10^9/L)	175.5 (123.8–218)	199 (147.3–242.5)[a]	.1
Thrombocytopenia (platelet count <100 x 10^9/L)	17.5% (7)	10.7% (6)[a]	.3
Pulmonary edema	2.5% (1)	1.8% (1)	.8
Placental lesions of maternal vascular malperfusion	72.5% (29)	42.1% (24)	.003

AST: aspartate aminotransferase; ALT: alanine aminotransferase.
Data are presented as median (interquartile range) or percentage (number of patients).
Mann–Whitney *U*-tests were used for continuous variables and Chi-square tests for categorical variables.
[a]n = 56; [b]n = 30; [c]n = 41; [d]n = 39; [e]n = 50.

888 (812–1781) pg/mL, unadjusted and adjusted $p=.03$; and with MVM vs. control 630 (448–4002) pg/mL, unadjusted $p=.02$, adjusted $p=.04$; Figure 2]. There was no significant difference in the median plasma MNRR1 concentrations between women with early preeclampsia without MVM lesions and those with an uncomplicated pregnancy (unadjusted $p=.4$, adjusted $p=.3$). By contrast, patients with late preeclampsia, regardless of the presence or absence of MVM lesions, had a significantly higher median (IQR) plasma MNRR1 concentration than women in the control group [with MVM 1609 (1392–3135) pg/mL vs. control 910 (526–6178), unadjusted $p=.1$, adjusted $p=.045$; and without MVM 2023 (1578–8936) pg/mL vs. control, unadjusted and adjusted $p=.01$; Figure 2]. There was no significant difference in the median plasma MNRR1 concentration between patients with and without MVM lesions in late preeclampsia (unadjusted and adjusted $p=.1$).

Discussion

Principal findings of the study

1) Women with preeclampsia, either early or late disease, had a plasma MNRR1 concentration 2- to 2.6-fold higher than uncomplicated pregnant women; 2) among women with early preeclampsia, those with MVM lesions had a higher MNRR1 concentration compared to those without MVM lesions and to women with an uncomplicated pregnancy; and 3) women with late preeclampsia had a higher plasma MNRR1 concentration than uncomplicated pregnant women regardless of the presence or absence of MVM lesions in the placenta.

Preeclampsia and mitochondrial dysfunction

Given that placental oxidative stress can cause mitochondrial dysfunction and vice versa [51,84], several lines of evidence suggested that mitochondrial dysfunction plays a role in the pathogenesis of preeclampsia. First, preeclampsia is a condition frequently encountered in families with mitochondrial disorders [85–87]. Second, signs of mitochondrial dysfunction, such as changes in architecture (including size [88] and structure [89,90]) of the mitochondria in both the syncytiotrophoblast and the cytotrophoblast layers [88], decreased number of COX-positive mitochondria [91] and COX enzyme activity [88,92], impaired mitochondrial fusion [93,94], decreased lipid metabolism [94], and ATP production [93,94], have all been observed in the placentae of women with preeclampsia [49,51,88–96]. Third, the serum concentrations of mitofusin-2 [97], a mitochondrial fusion protein, and the circulating cell-free mitochondrial DNA copy number [98–100], a marker of mitochondrial dysfunction and inflammation, are higher in women with preeclampsia at the time of diagnosis than in those with an uncomplicated pregnancy. The increase in circulating mitochondrial DNA in women with preeclampsia could be observed as early as 20 weeks of gestation, supporting the role of mitochondrial dysfunction as a cause rather than a consequence of preeclampsia [101].

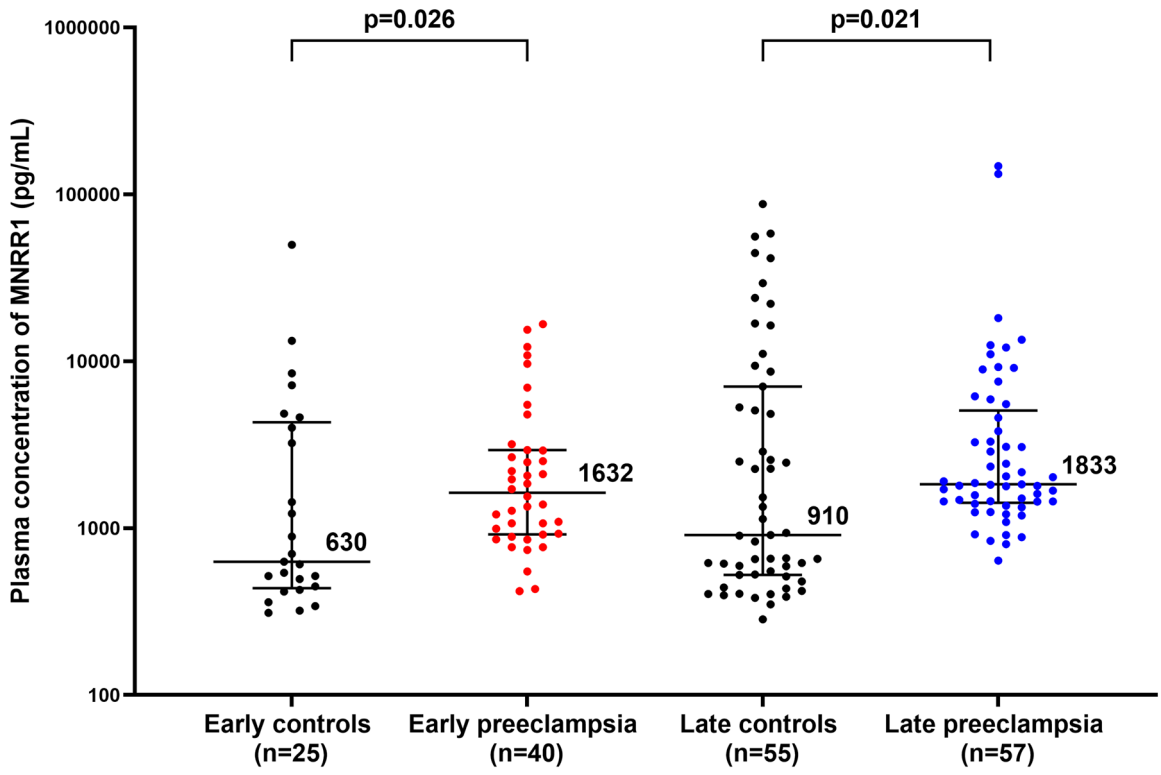

Figure 1. Plasma MNRR1 concentrations in pregnant women with preeclampsia and controls. The median (IQR) plasma concentration of MNRR1 was significantly higher in patients with early [1632 (924–2926) pg/mL vs. 630 (448–4002) pg/mL; $p = .03$, adjusted $p = .026$] and late [1833 (1441–5534) pg/mL vs. 910 (526–6178) pg/mL; $p = .001$, adjusted $p = .021$] preeclampsia compared to uncomplicated pregnant women. *Y*-axis data are presented in logarithmic scale.

MNRR1 in health and disease

MNRR1, a recently characterized bi-organellar protein encoded by the homonymous gene [102–104], is a member of the coiled-coil-helix-coiled-coil-helix (CHCH) domain-containing protein family, a group of evolutionarily conserved proteins [105,106] found in the mitocondrial intermembrane space and now recognized as cellular factors regulating cellular respiration, redox equilibrium, lipid homeostasis, and membrane dynamics. MNRR1 is mainly localized in the mitochondria [75] and plays a key role in oxidative phosphorylation by regulation of COX activity [74,75,107]. In the nucleus, MNRR1 is a transcription factor that promotes the transcription of the COX subunit 4 isoform 2 (*COX4I2*) gene and of MNRR1 itself under cellular hypoxic conditions [74,77]. Recently, our group reported that LPS-induced trophoblast inflammation is associated with a reduction in MNRR1 expression and organellar dysfunction [78]. Additional evidence for the role of MNRR1 in the pathogenesis of diseases comes from genetic studies which showed that mutations of MNRR1 are associated with neurodegenerative disorders such as Parkinson's disease [108–111], Alzheimer's disease, and Charcot-Marie-Tooth type 1A [78]. Moreover, an alteration of protein or transcript levels [75] is associated with Huntington's disease [112], lissencephaly [113], endometriosis [114], and malignancies such as hepatocellular carcinoma [115,116], non-small cell lung carcinoma [117–119], and invasive ductal carcinoma of the breast [120]. Little is known about the role of MNRR1 in pregnancy complications. Recently, Bosco et al. reported that MNRR1 is detectable in the plasma of non-pregnant woman, and its concentration does not differ from that of an uncomplicated pregnant woman [121]. Moreover, plasma MNRR1 concentration does not change with spontaneous labor at term but increases in the plasma of pregnant women complicated by infection and/or inflammation, such as clinical chorioamnionitis [121].

Plasma MNRR1 concentration is elevated in patients with preeclampsia

In the current study, maternal plasma MNRR1 concentration was higher than the controls in both early and late preeclampsia. However, there was no significant difference in plasma MNRR1 concentration between the two subgroups. Moreover, no significant correlations were observed between plasma MNRR1

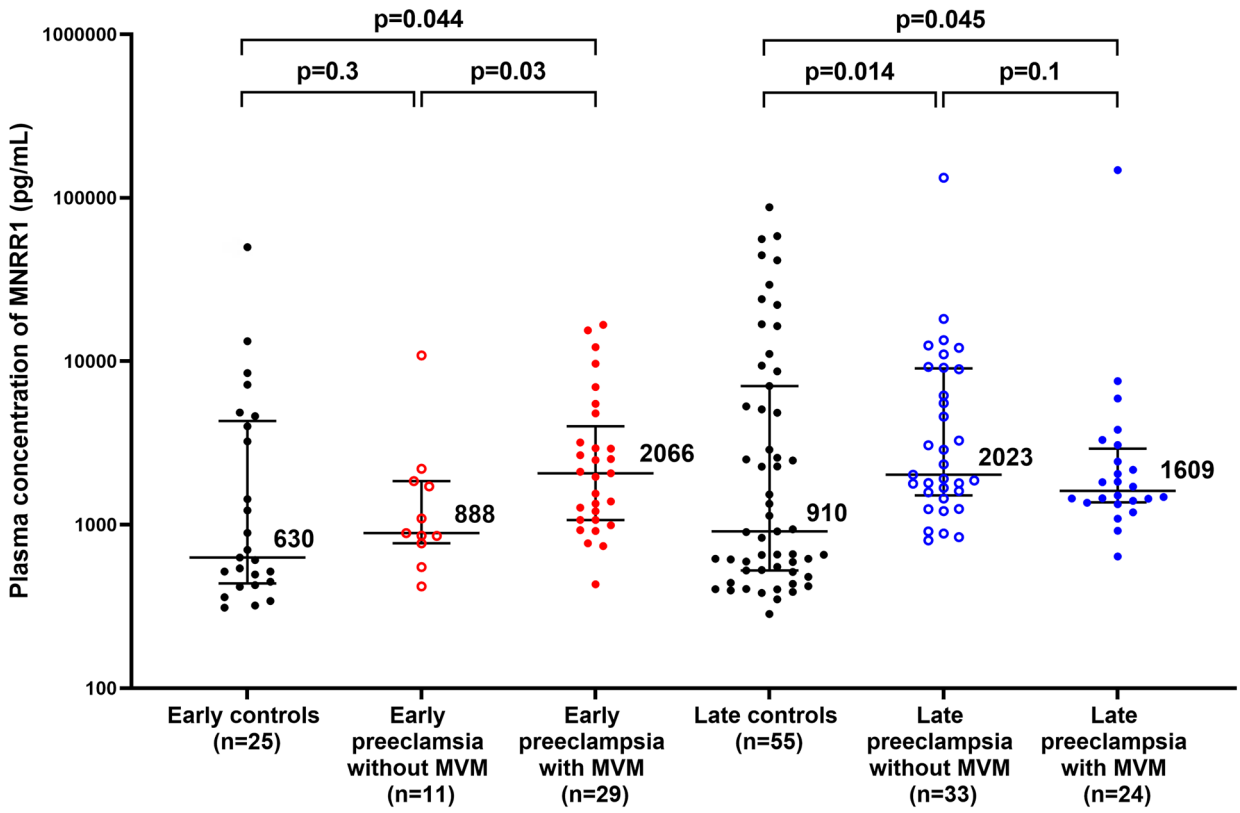

Figure 2. Plasma MNRR1 concentrations in women with preeclampsia stratified by the presence of placental lesions of maternal vascular malperfusion (MVM) in early and late preeclampsia compared to their respective controls. For early preeclampsia, the patients with MVM lesions in the placenta had the highest median (IQR) plasma concentration of MNRR1 among the three groups [with MVM 2066 (1070–3188) pg/mL vs. without MVM 888 (812–1781) pg/mL, $p = .03$; and with MVM vs. controls 630 (448–4002) pg/mL, $p = .018$, adjusted $p = .04$]. By contrast, in late preeclampsia, patients with and those without MVM lesions in the placenta had a significantly higher median (IQR) plasma MNRR1 concentration than women in the control group [with MVM 1609 (1392–3135) pg/mL vs. controls 910 (526–6178), $p = .1$, adjusted $p = .045$; and without MVM 2023 (1578–8936) pg/mL vs. controls, $p = .01$]. *Y*-axis data are presented in logarithmic scale.

concentration and severity of preeclampsia as determined by blood pressure levels, gestational age at delivery, or birthweight. Due to substantial overlapping of plasma MNRR1 concentration between women with preeclampsia and those with an uncomplicated pregnancy, this mitochondrial protein, if used solely, is unlikely to be a good biomarker to differentiate preeclampsia from normal pregnancy.

Plasma MNRR1 concentration is elevated in early preeclampsia with placental lesions of MVM

Preeclampsia is currently viewed as a vascular disorder resulting from multiple and overlapping pathologic processes [1,7]. However, an anti-angiogenic state has emerged as a major mechanism of disease in preeclampsia, especially in early-onset disease [14,26,27,122]. An imbalance between plasma concentrations of angiogenic [low placental growth factor (PlGF)] and anti-angiogenic [high soluble fms-like tyrosine kinase (sFlt)-1] factors has been observed in women with preeclampsia both prior to [123–129] and at the time of clinical diagnosis [14,130–132]. These abnormalities correlate with disease severity [14,123,130] and can identify women who will develop adverse perinatal outcomes better than clinical symptoms and standard laboratory tests [133–143]. Patients with preeclampsia and the presence of placental lesions consistent with MVM are associated with an anti-angiogenic state or a low maternal plasma angiogenic index-1 (PlGF/sFlt-1 ratio) concentration [67,68].

In the current study, women diagnosed with early preeclampsia and with placental lesions of MVM had a median plasma MNNR1 concentration approximately 3-fold higher than the controls. An experimental study by Jiang et al. reported that repeated administration of recombinant sFlt-1 agents to pregnant mice not only induced clinical symptoms of preeclampsia but also mitochondrial swelling and apoptosis markers in the placenta (upregulation of apoptotic Bax and cleaved

caspase-3 proteins as well as downregulation of antiapoptotic Bcl-2 protein) as well as markers of oxidative stress in maternal blood (i.e. increased serum malondialdehyde and decreased superoxide dismutase concentrations) compared to controls [144]. These findings suggested that an anti-angiogenic state can induce mitochondrial dysfunction in the placenta. Moreover, in a rat model of preeclampsia, reduced uterine perfusion pressure can induce mitochondrial dysfunction (i.e. impaired mitochondrial respiration as measured by oxygen usage per weight of mitochondria) and increased mitochondrial ROS production in the placenta and kidney as well as in endothelial cells exposed to circulating factors from the ischemic placenta [145]. However, in the human placenta, mitochondrial COX activity inversely correlates with syncytiotrophoblast sFlt-1 protein expression [88]. Therefore, it is possible that excess MNRR1 in the maternal blood of women with early preeclampsia with placental lesions of MVM was released from stressed or injured trophoblasts in response to uteroplacental ischemia or to an anti-angiogenic state in the placenta. Of note, mitochondrial abnormalities in the human placenta have been observed more frequently in early rather than late preeclampsia [49,146–148].

Women with early preeclampsia without MVM lesions had a slightly higher plasma MNRR1 concentration than those in the control group. However, the difference did not reach statistical significance. This finding is consistent with the observation of Rana et al. who reported that among women with preterm preeclampsia, those with a normal serum angiogenic–antiangiogenic profile, had fewer maternal complications [149] and, therefore, probably a lesser degree of injured trophoblasts, placental oxidative stress, and systemic inflammation.

Patients with late preeclampsia regardless of placental lesions of MVM had a higher plasma MNRR1 concentration than controls

Traditionally, late preeclampsia is considered a maternal syndrome (also known as "maternal preeclampsia") rather than a placental syndrome, since this subtype frequently occurs in patients with a high body mass index (BMI) and preexisting vascular disease, and the placenta has MVM lesions less frequently than in preterm preeclampsia [150,151]. Patients with late preeclampsia had evidence of mitochondrial dysfunction; however, the mechanisms seems to be different from early preeclampsia [49,146,148]. Indeed, Holland et al. reported that hydrogen peroxide production and antioxidant activity were increased in term preeclamptic placentae, whereas preterm preeclamptic placentae had reduced hydrogen peroxide production and reduced function of the antioxidant superoxide dismutase compared to control placentae [148]. In addition, the expression level of mitochondrial complexes and markers of mitochondrial fission/fusion and apoptosis were differentially affected in term compared to preterm preeclamptic placentae [148]. For example, mitochondrial respiration and content (assessed by the mtDNA/nDNA ratio) were higher in term compared to those in preterm preeclamptic placentae. However, a lower respiratory reserve capacity was observed in the mitochondria of placentae from women with term preeclampsia, possibly indicating a placental mitochondrial adaptation characterized by a compensatory antioxidant and mitochondrial response. However, the findings of mitochondria abnormalities in late preeclampsia are inconsistent among studies [49,93,94,97,146–148].

Recently, we reported that patients with preeclampsia at term can be classified into two clusters according to the PlGF/sFlt-1 ratio [69]. These two clusters have different clinical characteristics and frequency of adverse perinatal outcomes [69]. About one-half of women with preeclampsia at term had an abnormal angiogenic profile. Women in this group were younger and more often had placental lesions consistent with MVM. Unlike early preeclampsia when defective deep placentation is believed to be a culprit, syncytiotrophoblast stress, caused by physical constraints on placental growth, and cytotrophoblast senescence have been proposed to explain the excess trophoblastic release of anti-angiogenic factors in this subgroup [28]. However, another one-half of women with preeclampsia at term had a normal angiogenic profile. Women in this group had a higher frequency of chronic hypertension and were more likely to have a higher BMI than those with an abnormal angiogenic profile [69]. The frequency of placental lesions of MVM in this group is only slightly higher than that observed in normal pregnancies, suggesting that other pathologic mechanisms (i.e. metabolic syndrome) may be implicated [69]. These observations might explain the inconsistent findings of mitochondrial research in the placentae of women with late preeclampsia.

Findings that indicate the median plasma MNRR1 concentration was 1.5-fold higher in women with late preeclampsia with placental lesions consistent with MVM compared to that in the control group could be explained by the presence of the anti-angiogenic state, similar to that observed in early preeclampsia, albeit at a lower level of anti-angiogenic factors and a milder degree of stressed trophoblasts and/or mitochondrial dysfunction. By contrast, the 2-fold elevation of plasma

MNRR1 concentration in women with late preeclampsia without MVM lesions in the placenta is likely to result from different pathways other than injured or stressed trophoblasts. One possibility is that MNRR1 is released from vascular endothelial cells or leukocytes since most of these patients might have a mild degree of leukocyte activation and intravascular inflammation due to preexisting conditions, such as obesity or chronic hypertension. Since the pathologic pathway of this subgroup of preeclampsia is currently unclear, further studies are needed to understand the source and consequence of the excess MNRR1 release. Nevertheless, the plasma MNRR1 concentration cannot be used as a biomarker to differentiate between late preeclampsia with and without MVM lesions in the placenta.

Strength and limitations of the study

This is the first study to report the maternal plasma concentration of MNRR1, a recently characterized mitochondrial regulator protein, in patients with preeclampsia stratified by gestational age at delivery into early and late disease. Moreover, all patients with preeclampsia had a placental histologic examination and sampling of the placenta according to standardized protocols. The patients were further subclassified according to the presence or absence of MVM lesions, which is considered the histologic counterpart of the anti-angiogenic state, the major established pathway to clinical syndromes of preeclampsia.

A limitation of this study is that the temporal relationship between changes in MNRR1 concentrations and the clinical diagnosis of preeclampsia could not be elucidated due to the cross-sectional nature of the study. In addition, we did not measure plasma PlGF or sFlt-1 concentrations and thus could not correlate these results with angiogenic or anti-angiogenic factors concentrations. The patients with late preeclampsia enrolled in this study had a high prevalence of severe features [49/57 (86%)]. This could be attributed to the nature of severe features in patients who were more likely to be admitted or referred to a single tertiary care center in the area at that time than those without severe features. The predominance of African-American participants [155/177 (88%)] in the study might affect generalizability.

Conclusions

Maternal plasma concentration of MNRR1, a mitochondrial regulator protein, is elevated in women with preeclampsia at the time of diagnosis, and this is particularly the case in women with early preeclampsia and placental lesions consistent with MVM. It is of interest that plasma MNRR1 concentrations were elevated in patients with late preeclampsia regardless of the presence or absence of placental lesions of MVM. Excess concentrations of MNRR1 in the maternal plasma of women with preeclampsia could be a part of mitochondrial dysfunction, intravascular inflammation, or other unknown pathologic processes.

Acknowledgements

The authors thank Maureen McGerty, MA, (Pregnancy Research Branch, NICHD/NIH/DHHS) for her critical reading of the manuscript and editorial support.

Author contributions

Conceptualization, methodology, validation: Tinnakorn Chaiworapongsa, Roberto Romero, Lawrence Grossman, Siddhesh Aras, Manaphat Suksai, and Mariachiara Bosco.
Data curation, writing, original draft preparation: Manaphat Suksai, Mariachiara Bosco, Tinnakorn Chaiworapongsa, Nardhy Gomez-Lopez, and Adi Tarca.
Visualization, writing, review, and editing: Manaphat Suksai, Eunjung Jung, Arun Meyyazhagan, Marcia Arenas-Hernandez, Francesca Gotsch, Lawrence Grossman, Siddhesh Aras, Piya Chaemsaithong, and Roberto Romero.
Formal analysis: Dereje Gudicha, Tinnakorn Chaiworapongsa, Manaphat Suksai, Adi Tarca.
Resources: Tinnakorn Chaiworapongsa, Roberto Romero, Nardhy Gomez-Lopez, Marcia Arenas-Hernandez.
Supervision: Roberto Romero, Tinnakorn Chaiworapongsa, Adi Tarca, Nardhy Gomez-Lopez.
Each author approved the final version of the manuscript prior to its submission to the Journal.

Ethical Statement

This research complies with the guidelines for human studies and was conducted ethically in accordance with the World Medical Association Declaration of Helsinki. The study protocols (OH97-CH-N067, OH98-CH-N001, and OH99-CH-N056) were reviewed and approved by the Institutional Review Board of the *Eunice Kennedy Shriver* National Institute of Child Health and Human Development, National Institutes of Health, United States Department of Health and Human Services (NICHD/NIH/DHHS) and by the Human Investigation Committee of Wayne State University (IRB Nos.110605MP2F, 082403MP2F(5R), and 103108MP2F(RCR)).

Patient consent

Written informed consent was obtained from the study participants prior to the collection of maternal blood samples.

Disclosure statement

The funders had no role in the design of the study, in the collection, analyses, or interpretation of data, in the writing of the manuscript, or in the decision to publish the results. Dr. Romero has contributed to this work as part of his official duties as an employee of the United States Federal Government.

Funding

This research was supported, in part, by the Perinatology Research Branch, Division of Obstetrics and Maternal-Fetal Medicine, Division of Intramural Research, *Eunice Kennedy Shriver* National Institute of Child Health and Human Development, National Institutes of Health, US Department of Health and Human Services (NICHD/NIH/DHHS); and, in part, with Federal funds from NICHD/NIH/DHHS under Contract No. HHSN275201300006C. Dr. Tarca and Dr. Gomez-Lopez were also supported by the Wayne State University Perinatal Initiative for Maternal, Perinatal and Child Health.

Data availability statement

All data generated or analyzed during this study are included in this article. Further inquiries can be directed to the corresponding author at romeror@mail.nih.gov (Dr. Romero).

References

[1] Erez O, Romero R, Jung E, et al. Preeclampsia and eclampsia: the conceptual evolution of a syndrome. Am J Obstet Gynecol. 2022;226(2s):1–19. doi: 10.1016/j.ajog.2021.12.001.

[2] Brown MA, Magee LA, Kenny LC, et al. The hypertensive disorders of pregnancy: ISSHP classification, diagnosis & management recommendations for international practice. Pregnancy Hypertens. 2018;13:291–310. doi: 10.1016/j.preghy.2018.05.004.

[3] Gestational Hypertension and Preeclampsia: ACOG Practice Bulletin, Number 222. Obstet Gynecol. 2020;135(6):e237–e260.

[4] Say L, Chou D, Gemmill A, et al. Global causes of maternal death: a WHO systematic analysis. Lancet Glob Health. 2014;2(6):e323–e333. doi: 10.1016/S2214-109X(14)70227-X.

[5] Executive summary: workshop on preeclampsia, January 25–26, 2021, cosponsored by the society for maternal-Fetal medicine and the preeclampsia foundation. Am J Obstet Gynecol. 2021;225(3):B2–B7.

[6] Joseph KS, Boutin A, Lisonkova S, et al. Maternal mortality in the United States: recent trends, current status, and future considerations. Obstet Gynecol. 2021;137(5):763–771. doi: 10.1097/AOG.0000000000004361.

[7] Jung E, Romero R, Yeo L, et al. The etiology of preeclampsia. Am J Obstet Gynecol. 2022; 226(2s):S844–S866. doi: 10.1016/j.ajog.2021.11.1356.

[8] Roberts JM, Taylor RN, Musci TJ, et al. Preeclampsia: an endothelial cell disorder. Am J Obstet Gynecol. 1989;161(5):1200–1204. doi: 10.1016/0002-9378(89)90665-0.

[9] Hubel CA. Dyslipidemia, iron, and oxidative stress in preeclampsia: assessment of maternal and feto-placental interactions. Semin Reprod Endocrinol. 1998;16(1):75–92. doi: 10.1055/s-2007-1016255.

[10] Redman CW, Sacks GP, Sargent IL. Preeclampsia: an excessive maternal inflammatory response to pregnancy. Am J Obstet Gynecol. 1999;180(2 Pt 1):499–506. doi: 10.1016/s0002-9378(99)70239-5.

[11] Gervasi MT, Chaiworapongsa T, Pacora P, et al. Phenotypic and metabolic characteristics of monocytes and granulocytes in preeclampsia. Am J Obstet Gynecol. 2001;185(4):792–797. doi: 10.1067/mob.2001.117311.

[12] Chaiworapongsa T, Romero R, Yoshimatsu J, et al. Soluble adhesion molecule profile in normal pregnancy and pre-eclampsia. J Matern Fetal Neonatal Med. 2002;12(1):19–27. doi: 10.1080/jmf.12.1.19.27.

[13] Chaiworapongsa T, Yoshimatsu J, Espinoza J, et al. Evidence of in vivo generation of thrombin in patients with small-for-gestational-age fetuses and pre-eclampsia. J Matern Fetal Neonatal Med. 2002;11(6):362–367. doi: 10.1080/jmf.11.6.362.367.

[14] Maynard SE, Min JY, Merchan J, et al. Excess placental soluble fms-like tyrosine kinase 1 (sFlt1) may contribute to endothelial dysfunction, hypertension, and proteinuria in preeclampsia. J Clin Invest. 2003;111(5):649–658. doi: 10.1172/JCI17189.

[15] Burton GJ, Yung HW, Cindrova-Davies T, et al. Placental endoplasmic reticulum stress and oxidative stress in the pathophysiology of unexplained intrauterine growth restriction and early onset preeclampsia. Placenta. 2009;30 Suppl A(Suppl):S43–S48. doi: 10.1016/j.placenta.2008.11.003.

[16] Rodgers GM, Taylor RN, Roberts JM. Preeclampsia is associated with a serum factor cytotoxic to human endothelial cells [in vitro research support, U.S. Gov't, P.H.S.]. Am J Obstet Gynecol. 1988;159(4):908–914. doi: 10.1016/s0002-9378(88)80169-8.

[17] Brosens I, Pijnenborg R, Vercruysse L, et al. The "great obstetrical syndromes" are associated with disorders of deep placentation. Am J Obstet Gynecol. 2011;204(3):193–201. doi: 10.1016/j.ajog.2010.08.009.

[18] Hauth JC, Clifton RG, Roberts JM, et al. Maternal insulin resistance and preeclampsia. Am J Obstet Gynecol. 2011;204(4):327.e1-6–327.e6. doi: 10.1016/j.ajog.2011.02.024.

[19] Redman CW, Tannetta DS, Dragovic RA, et al. Review: does size matter? Placental debris and the pathophysiology of pre-eclampsia. Placenta. 2012;33(Suppl):S48–S54. doi: 10.1016/j.placenta.2011.12.006.

[20] Major HD, Campbell RA, Silver RM, et al. Synthesis of sFlt-1 by platelet-monocyte aggregates contributes to the pathogenesis of preeclampsia. Am J Obstet Gynecol. 2014;210(6):547.e1–7. doi: 10.1016/j.ajog.2014.01.024.

[21] Redman CW, Staff AC. Preeclampsia, biomarkers, syncytiotrophoblast stress, and placental capacity. Am J Obstet Gynecol. 2015;213(4 Suppl)S9.e1–S9.e4. doi: 10.1016/j.ajog.2015.08.003.

[22] Yung HW, Colleoni F, Dommett E, et al. Noncanonical mitochondrial unfolded protein response impairs placental oxidative phosphorylation in early-onset pre-

eclampsia. Proc Natl Acad Sci U S A. 2019;116(36):18109–18118. doi: 10.1073/pnas.1907548116.

[23] Levine L, Habertheuer A, Ram C, et al. Syncytiotrophoblast extracellular microvesicle profiles in maternal circulation for noninvasive diagnosis of preeclampsia. Sci Rep. 2020;10(1):6398. doi: 10.1038/s41598-020-62193-7.

[24] Burwick RM, Feinberg BB. Complement activation and regulation in preeclampsia and hemolysis, elevated liver enzymes, and low platelet count syndrome. Am J Obstet Gynecol. 2022;226(2S):S1059–S1070.

[25] Aye I, Aiken CE, Charnock-Jones DS, et al. Placental energy metabolism in health and disease-significance of development and implications for preeclampsia. Am J Obstet Gynecol. 2020;226(2S):S928–S944.

[26] Stepan H, Hund M, Andraczek T. Combining biomarkers to predict pregnancy complications and redefine preeclampsia: the angiogenic-placental syndrome. Hypertension. 2020;75(4):918–926. doi: 10.1161/HYPERTENSIONAHA.119.13763.

[27] Rana S, Burke SD, Karumanchi SA. Imbalances in circulating angiogenic factors in the pathophysiology of preeclampsia and related disorders. Am J Obstet Gynecol. 2022;226(2S):S1019–S1034. doi: 10.1016/j.ajog.2020.10.022.

[28] Redman CWG, Staff AC, Roberts JM. Syncytiotrophoblast stress in preeclampsia: the convergence point for multiple pathways. Am J Obstet Gynecol. 2022;226(2s):S907–s927. doi: 10.1016/j.ajog.2020.09.047.

[29] Roberts JM, Hubel CA, Taylor RN. Endothelial dysfunction yes, cytotoxicity no!. Am J Obstet Gynecol. 1995;173(3 Pt 1):978–979. doi: 10.1016/0002-9378(95)90393-3.

[30] Cindrova-Davies T, Sanders DA, Burton GJ, et al. Soluble FLT1 sensitizes endothelial cells to inflammatory cytokines by antagonizing VEGF receptor-mediated signalling. Cardiovasc Res. 2011;89(3):671–679. doi: 10.1093/cvr/cvq346.

[31] Lamarca B. Endothelial dysfunction. An important mediator in the pathophysiology of hypertension during pre-eclampsia. Minerva Ginecol. 2012;64(4):309–320.

[32] Sacks GP, Studena K, Sargent K, et al. Normal pregnancy and preeclampsia both produce inflammatory changes in peripheral blood leukocytes akin to those of sepsis. Am J Obstet Gynecol. 1998;179(1):80–86. doi: 10.1016/s0002-9378(98)70254-6.

[33] Gotsch F, Romero R, Friel L, et al. CXCL10/IP-10: a missing link between inflammation and anti-angiogenesis in preeclampsia? J Matern Fetal Neonatal Med. 2007;20(11):777–792. doi: 10.1080/14767050701483298.

[34] Boij R, Svensson J, Nilsson-Ekdahl K, et al. Biomarkers of coagulation, inflammation, and angiogenesis are independently associated with preeclampsia. Am J Reprod Immunol. 2012;68(3):258–270. doi: 10.1111/j.1600-0897.2012.01158.x.

[35] Kucukgoz Gulec U, Tuncay Ozgunen F, Baris Guzel A, et al. An analysis of C-reactive protein, procalcitonin, and D-dimer in pre-eclamptic patients. Am J Reprod Immunol. 2012;68(4):331–337. doi: 10.1111/j.1600-0897.2012.01171.x.

[36] Lau SY, Guild SJ, Barrett CJ, et al. Tumor necrosis factor-alpha, interleukin-6, and interleukin-10 levels are altered in preeclampsia: a systematic review and meta-analysis. Am J Reprod Immunol. 2013;70(5):412–427. doi: 10.1111/aji.12138.

[37] Stampalija T, Chaiworapongsa T, Romero R, et al. Maternal plasma concentrations of sST2 and angiogenic/anti-angiogenic factors in preeclampsia. J Matern Fetal Neonatal Med. 2013; Sep26(14):1359–1370. doi: 10.3109/14767058.2013.784256.

[38] Romero R, Chaemsaithong P, Tarca AL, et al. Maternal plasma-soluble ST2 concentrations are elevated prior to the development of early and late onset preeclampsia - a longitudinal study. J Matern Fetal Neonatal Med. 2018;31(4):418–432. doi: 10.1080/14767058.2017.1286319.

[39] Burwick RM, Lokki AI, Fleming SD, et al. Editorial: innate immunity in normal and adverse pregnancy. Front Immunol. 2021;12:646596. doi: 10.3389/fimmu.2021.646596.

[40] Kanninen T, Jung E, Gallo DM, et al. Soluble suppression of tumorigenicity-2 in pregnancy with a small-for-gestational-age fetus and with preeclampsia. J Matern Fetal Neonatal Med. 2023;36(1):2153034. doi: 10.1080/14767058.2022.2153034.

[41] Wang Y, Walsh SW. Placental mitochondria as a source of oxidative stress in pre-eclampsia. Placenta. 1998;19(8):581–586. doi: 10.1016/s0143-4004(98)90018-2.

[42] Wang Y, Walsh SW. Increased superoxide generation is associated with decreased superoxide dismutase activity and mRNA expression in placental trophoblast cells in pre-eclampsia. Placenta. 2001;22(2–3):206–212. doi: 10.1053/plac.2000.0608.

[43] Myatt L, Cui X. Oxidative stress in the placenta. Histochem Cell Biol. 2004;122(4):369–382. doi: 10.1007/s00418-004-0677-x.

[44] Moretti M, Phillips M, Abouzeid A, et al. Increased breath markers of oxidative stress in normal pregnancy and in preeclampsia. Am J Obstet Gynecol. 2004; May190(5):1184–1190. doi: 10.1016/j.ajog.2003.11.008.

[45] Matsubara K, Matsubara Y, Hyodo S, et al. Role of nitric oxide and reactive oxygen species in the pathogenesis of preeclampsia. J Obstet Gynaecol Res. 2010;36(2):239–247. doi: 10.1111/j.1447-0756.2009.01128.x.

[46] Burton GJ, Jauniaux E. Oxidative stress. Best Pract Res Clin Obstet Gynaecol. 2011;25(3):287–299. doi: 10.1016/j.bpobgyn.2010.10.016.

[47] Sánchez-Aranguren LC, Prada CE, Riaño-Medina CE, et al. Endothelial dysfunction and preeclampsia: role of oxidative stress. Front Physiol. 2014;5:372. doi: 10.3389/fphys.2014.00372.

[48] Schoots MH, Gordijn SJ, Scherjon SA, et al. Oxidative stress in placental pathology. Placenta. 2018;69:153–161. doi: 10.1016/j.placenta.2018.03.003.

[49] Marín R, Chiarello DI, Abad C, et al. Oxidative stress and mitochondrial dysfunction in early-onset and late-onset preeclampsia. Biochim Biophys Acta Mol Basis Dis. 2020;11866(12):165961. doi: 10.1016/j.bbadis.2020.165961.

[50] Ferreira RC, Fragoso MBT, Bueno NB, et al. Oxidative stress markers in preeclamptic placentas: a systematic review with meta-analysis. Placenta. 2020;99:89–100. doi: 10.1016/j.placenta.2020.07.023.

[51] Smith AN, Wang X, Thomas DG, et al. The role of mitochondrial dysfunction in preeclampsia: causative factor or collateral damage? Am J Hypertens. 2021;34(5):442–452. doi: 10.1093/ajh/hpab003.

[52] Ogden E, Hildebrand GJ, Page EW. Rise of blood pressure during ischemia of the gravid uterus. Proc Soc Exp

Biol Med. 1940;43(1):49–51. doi: 10.3181/00379727-43-11091P.
[53] Browne JC, Veall N. The maternal placental blood flow in normotensive and hypertensive women. J Obstet Gynaecol Br Emp. 1953;60(2):141–147. doi: 10.1111/j.1471-0528.1953.tb07668.x.
[54] Kumar D. Chronic placental ischemia in relation to toxemias of pregnancy: a preliminary report. Am J Obstet Gynecol. 1962;84(10):1323–1329. doi: 10.1016/S0002-9378(16)35742-8.
[55] Berger M, Cavanagh D. Toxemia of pregnancy: the hypertensive effect of acute experimental placental ischemia. Am J Obstet Gynecol. 1963;87(3):293–305. doi: 10.1016/0002-9378(63)90528-3.
[56] Lunell NO, Nylund LE, Lewander R, et al. Uteroplacental blood flow in pre-eclampsia measurements with indium-113m and a computer-linked gamma camera. Clin Exp Hypertens B. 1982;1(1):105–117. doi: 10.3109/10641958209037184.
[57] Espinoza J, Romero R, Mee Kim Y, et al. Normal and abnormal transformation of the spiral arteries during pregnancy. J Perinat Med. 2006;34(6):447–458. doi: 10.1515/JPM.2006.089.
[58] Romero R, Kusanovic JP, Chaiworapongsa T, et al. Placental bed disorders in preterm labor, preterm PROM, spontaneous abortion and abruptio placentae [research support, N.I.H., intramural review]. Best Pract Res Clin Obstet Gynaecol. 2011;25(3):313–327. doi: 10.1016/j.bpobgyn.2011.02.006.
[59] Staff AC, Fjeldstad HE, Fosheim IK, et al. Failure of physiological transformation and spiral artery atherosis: their roles in preeclampsia. Am J Obstet Gynecol. 2022;226(2s):S895–S906. doi: 10.1016/j.ajog.2020.09.026.
[60] Cindrova-Davies T, Spasic-Boskovic O, Jauniaux E, et al. Nuclear factor-kappa B, p38, and stress-activated protein kinase mitogen-activated protein kinase signaling pathways regulate proinflammatory cytokines and apoptosis in human placental explants in response to oxidative stress: effects of antioxidant vitamins. Am J Pathol. 2007;170(5):1511–1520. doi: 10.2353/ajpath.2007.061035.
[61] Conrad KP, Benyo DF. Placental cytokines and the pathogenesis of preeclampsia. Am J Reprod Immunol. 1997;37(3):240–249. doi: 10.1111/j.1600-0897.1997.tb00222.x.
[62] Keelan JA, Mitchell MD. Placental cytokines and preeclampsia. Front Biosci. 2007;12(1):2706–2727. doi: 10.2741/2266.
[63] LaMarca BD, Ryan MJ, Gilbert JS, et al. Inflammatory cytokines in the pathophysiology of hypertension during preeclampsia. Curr Hypertens Rep. 2007;9(6):480–485. doi: 10.1007/s11906-007-0088-1.
[64] Rusterholz C, Hahn S, Holzgreve W. Role of placentally produced inflammatory and regulatory cytokines in pregnancy and the etiology of preeclampsia. Semin Immunopathol. 2007;29(2):151–162. doi: 10.1007/s00281-007-0071-6.
[65] von Dadelszen P, Magee LA, Roberts JM. Subclassification of preeclampsia. Hypertens Pregnancy. 2003;22(2):143–148. doi: 10.1081/PRG-120021060.
[66] Roberts JM, Rich-Edwards JW, McElrath TF, et al. Subtypes of preeclampsia: recognition and determining clinical usefulness. Hypertension. 2021;77(5):1430–1441. doi: 10.1161/HYPERTENSIONAHA.120.14781.
[67] Korzeniewski SJ, Romero R, Chaiworapongsa T, et al. Maternal plasma angiogenic index-1 (placental growth factor/soluble vascular endothelial growth factor receptor-1) is a biomarker for the burden of placental lesions consistent with uteroplacental underperfusion: a longitudinal case-cohort study. Am J Obstet Gynecol. 2016;214(5):629.e1–629.e17. doi: 10.1016/j.ajog.2015.11.015.
[68] Romero R, Jung E, Chaiworapongsa T, et al. Toward a new taxonomy of obstetrical disease: improved performance of maternal blood biomarkers for the great obstetrical syndromes when classified according to placental pathology. Am J Obstet Gynecol. 2022 Oct;227(4):615.e1–615.e25. doi: 10.1016/j.ajog.2022.04.015.
[69] Chaiworapongsa T, Romero R, Gotsch F, et al. Preeclampsia at term can be classified into two clusters with different clinical characteristics and outcomes based on angiogenic biomarkers in maternal blood. Am J Obstet Gynecol. 2023;228(5):569.e1–569.e24. doi: 10.1016/j.ajog.2022.11.001.
[70] DiMauro S, Schon EA. Mitochondrial respiratory-chain diseases. N Engl J Med. 2003;348(26):2656–2668. doi: 10.1056/NEJMra022567.
[71] Kühlbrandt W. Structure and function of mitochondrial membrane protein complexes. BMC Biol. 2015;13(1):89. doi: 10.1186/s12915-015-0201-x.
[72] Yu E, Mercer J, Bennett M. Mitochondria in vascular disease. Cardiovasc Res. 2012;95(2):173–182. doi: 10.1093/cvr/cvs111.
[73] Fisher JJ, Bartho LA, Perkins AV, et al. Placental mitochondria and reactive oxygen species in the physiology and pathophysiology of pregnancy. Clin Exp Pharmacol Physiol. 2020;47(1):176–184. doi: 10.1111/1440-1681.13172.
[74] Aras S, Bai M, Lee I, et al. MNRR1 (formerly CHCHD2) is a bi-organellar regulator of mitochondrial metabolism. Mitochondrion. 2015;20:43–51. doi: 10.1016/j.mito.2014.10.003.
[75] Grossman LI, Purandare N, Arshad R, et al. MNRR1, a biorganellar regulator of mitochondria. Oxid Med Cell Longev. 2017;2017:6739236. doi: 10.1155/2017/6739236.
[76] Purandare N, Somayajulu M, Hüttemann M, et al. The cellular stress proteins CHCHD10 and MNRR1 (CHCHD2): partners in mitochondrial and nuclear function and dysfunction. J Biol Chem. 2018;293(17):6517–6529. doi: 10.1074/jbc.RA117.001073.
[77] Aras S, Pak O, Sommer N, et al. Oxygen-dependent expression of cytochrome c oxidase subunit 4-2 gene expression is mediated by transcription factors RBPJ, CXXC5 and CHCHD2. Nucleic Acids Res. 2013;41(4):2255–2266. doi: 10.1093/nar/gks1454.
[78] Purandare N, Kunji Y, Xi Y, et al. Lipopolysaccharide induces placental mitochondrial dysfunction in murine and human systems by reducing MNRR1 levels via a TLR4-independent pathway. iScience. 2022;25(11):105342. doi: 10.1016/j.isci.2022.105342.
[79] ACOG practice bulletin. Diagnosis and management of preeclampsia and eclampsia. Obstet Gynecol. 2002;99(1):159–167.
[80] Alexander GR, Himes JH, Kaufman RB, et al. A United States national reference for fetal growth. Obstet

Gynecol. 1996;87(2):163–168. doi: 10.1016/0029-7844(95)00386-X.

[81] Chaiworapongsa T, Romero R, Erez O, et al. The prediction of fetal death with a simple maternal blood test at 20-24 weeks: a role for angiogenic index-1 (PlGF/sVEGFR-1 ratio). Am J Obstet Gynecol. 2017;217(6):682.e1–682.e13. doi: 10.1016/j.ajog.2017.10.001.

[82] Redline RW, Heller D, Keating S, et al. Placental diagnostic criteria and clinical correlation - a workshop report. Placenta. 2005;26 Suppl A:S114–S117. doi: 10.1016/j.placenta.2005.02.009.

[83] Khong TY, Mooney EE, Ariel I, et al. Sampling and definitions of placental lesions: Amsterdam placental workshop group consensus statement. Arch Pathol Lab Med. 2016;140(7):698–713. doi: 10.5858/arpa.2015-0225-CC.

[84] Karumanchi SA, Bdolah Y. Hypoxia and sFlt-1 in preeclampsia: the "chicken-and-egg" question. Endocrinology. 2004;145(11):4835–4837. doi: 10.1210/en.2004-1028.

[85] Berkowitz K, Monteagudo A, Marks F, et al. Mitochondrial myopathy and preeclampsia associated with pregnancy. Am J Obstet Gynecol. 1990;162(1):146–147. doi: 10.1016/0002-9378(90)90837-w.

[86] Folgerø T, Storbakk N, Torbergsen T, et al. Mutations in mitochondrial transfer ribonucleic acid genes in preeclampsia. Am J Obstet Gynecol. 1996;174(5):1626–1630. doi: 10.1016/s0002-9378(96)70619-1.

[87] Say RE, Whittaker RG, Turnbull HE, et al. Mitochondrial disease in pregnancy: a systematic review. Obstet Med. 2011;4(3):90–94. doi: 10.1258/om.2011.110008.

[88] Zsengellér ZK, Rajakumar A, Hunter JT, et al. Trophoblast mitochondrial function is impaired in preeclampsia and correlates negatively with the expression of soluble fms-like tyrosine kinase 1. Pregnancy Hypertens. 2016;6(4):313–319. doi: 10.1016/j.preghy.2016.06.004.

[89] Shanklin DR, Sibai BM. Ultrastructural aspects of preeclampsia. II. Mitochondrial changes. Am J Obstet Gynecol. 1990;163(3):943–953. doi: 10.1016/0002-9378(90)91102-i.

[90] Shi Z, Long W, Zhao C, et al. Comparative proteomics analysis suggests that placental mitochondria are involved in the development of pre-eclampsia. PLoS One. 2013;8(5):e64351. doi: 10.1371/journal.pone.0064351.

[91] Matsubara S, Minakami H, Sato I, et al. Decrease in cytochrome c oxidase activity detected cytochemically in the placental trophoblast of patients with pre-eclampsia. Placenta. 1997;18(4):255–259. doi: 10.1016/s0143-4004(97)80059-8.

[92] Furui T, Kurauchi O, Tanaka M, et al. Decrease in cytochrome c oxidase and cytochrome oxidase subunit I messenger RNA levels in preeclamptic pregnancies. Obstet Gynecol. 1994;84(2):283–288.

[93] Yu J, Guo X, Chen R, et al. Downregulation of mitofusin 2 in placenta is related to preeclampsia. Biomed Res Int. 2016;2016:6323086. doi: 10.1155/2016/6323086.

[94] Zhou X, Han TL, Chen H, et al. Impaired mitochondrial fusion, autophagy, biogenesis and dysregulated lipid metabolism is associated with preeclampsia. Exp Cell Res. 2017;359(1):195–204. doi: 10.1016/j.yexcr.2017.07.029.

[95] Muralimanoharan S, Maloyan A, Mele J, et al. MIR-210 modulates mitochondrial respiration in placenta with preeclampsia. Placenta. 2012;33(10):816–823. doi: 10.1016/j.placenta.2012.07.002.

[96] Holland O, Dekker Nitert M, Gallo LA, et al. Review: placental mitochondrial function and structure in gestational disorders. Placenta. 2017;54:2–9. doi: 10.1016/j.placenta.2016.12.012.

[97] Aydogan Mathyk B, Temel Yuksel I, Tayyar A, et al. Maternal serum mitofusin-2 levels in patients with preeclampsia: the possible role of mitochondrial dysfunction in preeclampsia. J Matern Fetal Neonatal Med. 2020;33(11):1861–1866. doi: 10.1080/14767058.2018.1532497.

[98] Qiu C, Hevner K, Enquobahrie DA, et al. A case-control study of maternal blood mitochondrial DNA copy number and preeclampsia risk. Int J Mol Epidemiol Genet. 2012;3(3):237–244.

[99] McCarthy C, Kenny LC. Therapeutically targeting mitochondrial redox signalling alleviates endothelial dysfunction in preeclampsia. Sci Rep. 2016;6(1):32683. doi: 10.1038/srep32683.

[100] Marschalek J, Wohlrab P, Ott J, et al. Maternal serum mitochondrial DNA (mtDNA) levels are elevated in preeclampsia - a matched case-control study. Pregnancy Hypertens. 2018;14:195–199. doi: 10.1016/j.preghy.2018.10.003.

[101] Williamson RD, McCarthy FP, Khashan AS, et al. Exploring the role of mitochondrial dysfunction in the pathophysiology of pre-eclampsia. Pregnancy Hypertens. 2018;13:248–253. doi: 10.1016/j.preghy.2018.06.012.

[102] Baughman JM, Nilsson R, Gohil VM, et al. A computational screen for regulators of oxidative phosphorylation implicates SLIRP in mitochondrial RNA homeostasis. PLoS Genet. 2009;5(8):e1000590. doi: 10.1371/journal.pgen.1000590.

[103] Nayak RR, Kearns M, Spielman RS, et al. Coexpression network based on natural variation in human gene expression reveals gene interactions and functions. Genome Res. 2009;19(11):1953–1962. doi: 10.1101/gr.097600.109.

[104] Gene [Internet] Bethesda (MD): National Library of Medicine (US), National Center for Biotechnology Information. 2004 (cited 2022 Dec 29). Available from: https://www.ncbi.nlm.nih.gov/gene/51142.

[105] Cavallaro G. Genome-wide analysis of eukaryotic twin CX9C proteins. Mol Biosyst. 2010;6(12):2459–2470. doi: 10.1039/c0mb00058b.

[106] Longen S, Bien M, Bihlmaier K, et al. Systematic analysis of the twin cx(9)c protein family. J Mol Biol. 2009;393(2):356–368. doi: 10.1016/j.jmb.2009.08.041.

[107] Aras S, Arrabi H, Purandare N, et al. Abl2 kinase phosphorylates Bi-organellar regulator MNRR1 in mitochondria, stimulating respiration. Biochim Biophys Acta Mol Cell Res. 2017;1864(2):440–448. doi: 10.1016/j.bbamcr.2016.11.029.

[108] Funayama M, Ohe K, Amo T, et al. CHCHD2 mutations in autosomal dominant late-onset parkinson's disease: a genome-wide linkage and sequencing study. Lancet Neurol. 2015;14(3):274–282. doi: 10.1016/S1474-4422(14)70266-2.

[109] Shi CH, Mao CY, Zhang SY, et al. CHCHD2 gene mutations in familial and sporadic parkinson's disease.

Neurobiol Aging. 2016;38:217.e9–217.e13. doi: 10.1016/j.neurobiolaging.2015.10.040.

[110] Yang X, Zhao Q, An R, et al. Mutational scanning of the CHCHD2 gene in han chinese patients with parkinson's disease and meta-analysis of the literature. Parkinsonism Relat Disord. 2016;29:42–46. doi: 10.1016/j.parkreldis.2016.05.032.

[111] Kee TR, Espinoza Gonzalez P, Wehinger JL, et al. Mitochondrial CHCHD2: disease-associated mutations, physiological functions, and current animal models. Front Aging Neurosci. 2021;13:660843. doi: 10.3389/fnagi.2021.660843.

[112] Feyeux M, Bourgois-Rocha F, Redfern A, et al. Early transcriptional changes linked to naturally occurring huntington's disease mutations in neural derivatives of human embryonic stem cells. Hum Mol Genet. 2012;21(17):3883–3895. doi: 10.1093/hmg/dds216.

[113] Shimojima K, Okumura A, Hayashi M, et al. CHCHD2 is down-regulated in neuronal cells differentiated from iPS cells derived from patients with lissencephaly. Genomics. 2015;106(4):196–203. doi: 10.1016/j.ygeno.2015.07.001.

[114] Ren Y, Wang X, Guo J, et al. CHCHD2 regulates mitochondrial function and apoptosis of ectopic endometrial stromal cells in the pathogenesis of endometriosis. Reprod Sci. 2022;29(8):2152–2164. doi: 10.1007/s43032-021-00831-9.

[115] Song R, Yang B, Gao X, et al. Cyclic adenosine monophosphate response element-binding protein transcriptionally regulates CHCHD2 associated with the molecular pathogenesis of hepatocellular carcinoma. Mol Med Rep. 2015;11(6):4053–4062. doi: 10.3892/mmr.2015.3256.

[116] Yao Y, Su J, Zhao L, et al. CHCHD2 promotes hepatocellular carcinoma and indicates poor prognosis of hepatocellular carcinoma patients. J Cancer. 2019;10(27):6822–6828. doi: 10.7150/jca.31158.

[117] Li L, Wei Y, To C, et al. Integrated omic analysis of lung cancer reveals metabolism proteome signatures with prognostic impact. Nat Commun. 2014;5(1):5469. doi: 10.1038/ncomms6469.

[118] Wei Y, Vellanki RN, Coyaud É, et al. CHCHD2 is coamplified with EGFR in NSCLC and regulates mitochondrial function and cell migration. Mol Cancer Res. 2015;13(7):1119–1129. doi: 10.1158/1541-7786.MCR-14-0165-T.

[119] Yin X, Xia J, Sun Y, et al. CHCHD2 is a potential prognostic factor for NSCLC and is associated with HIF-1a expression. BMC Pulm Med. 2020;20(1):40. doi: 10.1186/s12890-020-1079-0.

[120] Aras S, Maroun MC, Song Y, et al. Mitochondrial autoimmunity and MNRR1 in breast carcinogenesis. BMC Cancer. 2019;19(1):411. doi: 10.1186/s12885-019-5575-7.

[121] Bosco M, Romero R, Gallo DM, et al. Clinical chorioamnionitis at term is characterized by changes in the plasma concentration of CHCHD2/MNRR1, a mitochondrial protein. J Matern Fetal Neonatal Med. 2023;36(2):2222333. doi: 10.1080/14767058.2023.2222333.

[122] Chaiworapongsa T, Chaemsaithong P, Yeo L, et al. Pre-eclampsia part 1: current understanding of its pathophysiology. Nat Rev Nephrol. 2014;10(8):466–480. doi: 10.1038/nrneph.2014.102.

[123] Levine RJ, Maynard SE, Qian C, et al. Circulating angiogenic factors and the risk of preeclampsia. N Engl J Med. 2004;350(7):672–683. doi: 10.1056/NEJMoa031884.

[124] Chaiworapongsa T, Romero R, Kim YM, et al. Plasma soluble vascular endothelial growth factor receptor-1 concentration is elevated prior to the clinical diagnosis of pre-eclampsia. J Matern Fetal Neonatal Med. 2005;17(1):3–18. doi: 10.1080/14767050400028816.

[125] Moore Simas TA, Crawford SL, Solitro MJ, et al. Angiogenic factors for the prediction of preeclampsia in high-risk women. Am J Obstet Gynecol. 2007;197(3):244.e1–244.e8. doi: 10.1016/j.ajog.2007.06.030.

[126] Stepan H, Unversucht A, Wessel N, et al. Predictive value of maternal angiogenic factors in second trimester pregnancies with abnormal uterine perfusion. Hypertension. 2007;49(4):818–824. doi: 10.1161/01.HYP.0000258404.21552.a3.

[127] Romero R, Nien JK, Espinoza J, et al. A longitudinal study of angiogenic (placental growth factor) and anti-angiogenic (soluble endoglin and soluble vascular endothelial growth factor receptor-1) factors in normal pregnancy and patients destined to develop preeclampsia and deliver a small for gestational age neonate. J Matern Fetal Neonatal Med. 2008;21(1):9–23. doi: 10.1080/14767050701830480.

[128] Powers RW, Jeyabalan A, Clifton RG, et al. Soluble fms-Like tyrosine kinase 1 (sFlt1), endoglin and placental growth factor (PlGF) in preeclampsia among high risk pregnancies. PLoS One. 2010;5(10):e13263. doi: 10.1371/journal.pone.0013263.

[129] Khalil A, Maiz N, Garcia-Mandujano R, et al. Longitudinal changes in maternal serum placental growth factor and soluble fms-like tyrosine kinase-1 in women at increased risk of pre-eclampsia. Ultrasound Obstet Gynecol. 2016;47(3):324–331. doi: 10.1002/uog.15750.

[130] Chaiworapongsa T, Romero R, Espinoza J, et al. Evidence supporting a role for blockade of the vascular endothelial growth factor system in the pathophysiology of preeclampsia. Young investigator award. Am J Obstet Gynecol. 2004;190(6):1541–1547. doi: 10.1016/j.ajog.2004.03.043.

[131] Vaisbuch E, Whitty JE, Hassan SS, et al. Circulating angiogenic and antiangiogenic factors in women with eclampsia. Am J Obstet Gynecol. 2011;204(2):152.e1–152.e9. doi: 10.1016/j.ajog.2010.08.049.

[132] Verlohren S, Herraiz I, Lapaire O, et al. New gestational phase-specific cutoff values for the use of the soluble fms-like tyrosine kinase-1/placental growth factor ratio as a diagnostic test for preeclampsia. Hypertension. 2014;63(2):346–352. doi: 10.1161/HYPERTENSIONAHA.113.01787.

[133] Chaiworapongsa T, Romero R, Savasan ZA, et al. Maternal plasma concentrations of angiogenic/anti-angiogenic factors are of prognostic value in patients presenting to the obstetrical triage area with the suspicion of preeclampsia. J Matern Fetal Neonatal Med. 2011;24(10):1187–1207. doi: 10.3109/14767058.2011.589932.

[134] Rana S, Powe CE, Salahuddin S, et al. Angiogenic factors and the risk of adverse outcomes in women with suspected preeclampsia. Circulation. 2012;125(7):911–919. doi: 10.1161/CIRCULATIONAHA.111.054361.

[135] Chappell LC, Duckworth S, Seed PT, et al. Diagnostic accuracy of placental growth factor in women with suspected preeclampsia: a prospective multicenter study. Circulation. 2013;128(19):2121–2131. doi: 10.1161/CIRCULATIONAHA.113.003215.

[136] Chaiworapongsa T, Romero R, Korzeniewski SJ, et al. Plasma concentrations of angiogenic/anti-angiogenic factors have prognostic value in women presenting with suspected preeclampsia to the obstetrical triage area: a prospective study. J Matern Fetal Neonatal Med. 2014;27(2):132–144. doi: 10.3109/14767058.2013.806905.

[137] Zeisler H, Llurba E, Chantraine F, et al. Predictive value of the sFlt-1: plGF ratio in women with suspected preeclampsia. N Engl J Med. 2016;374(1):13–22. doi: 10.1056/NEJMoa1414838.

[138] Salahuddin S, Wenger JB, Zhang D, et al. KRYPTOR-automated angiogenic factor assays and risk of preeclampsia-related adverse outcomes. Hypertens Pregnancy. 2016;35(3):330–345. doi: 10.3109/10641955.2016.1148162.

[139] Sovio U, Gaccioli F, Cook E, et al. Prediction of preeclampsia using the soluble fms-Like tyrosine kinase 1 to placental growth factor ratio: a prospective cohort study of unselected nulliparous women. Hypertension. 2017;69(4):731–738. doi: 10.1161/HYPERTENSIONAHA.116.08620.

[140] Barton JR, Woelkers DA, Newman RB, et al. Placental growth factor predicts time to delivery in women with signs or symptoms of early preterm preeclampsia: a prospective multicenter study. Am J Obstet Gynecol. 2020;222(3):259.e1–259.e11. doi: 10.1016/j.ajog.2019.09.003.

[141] Binder J, Kalafat E, Palmrich P, et al. Angiogenic markers and their longitudinal change for predicting adverse outcomes in pregnant women with chronic hypertension. Am J Obstet Gynecol. 2021;225(3):305.e1–305.e14. doi: 10.1016/j.ajog.2021.03.041.

[142] Dröge LA, Perschel FH, Stütz N, et al. Prediction of preeclampsia-Related adverse outcomes with the sFlt-1 (soluble fms-Like tyrosine kinase 1)/PlGF (placental growth factor)-ratio in the clinical routine: a Real-World study. Hypertension. 2021;77(2):461–471. doi: 10.1161/HYPERTENSIONAHA.120.15146.

[143] Dathan-Stumpf A, Czarnowsky V, Hein V, et al. Real-world data on the clinical use of angiogenic factors in pregnancies with placental dysfunction. Am J Obstet Gynecol. 2022;226(2S):S1037–S1047. doi: 10.1016/j.ajog.2020.10.028.

[144] Jiang Z, Zou Y, Ge Z, et al. A role of sFlt-1 in oxidative stress and apoptosis in human and mouse Pre-Eclamptic trophoblasts. Biol Reprod. 2015;93(3):73. doi: 10.1095/biolreprod.114.126227.

[145] Vaka VR, McMaster KM, Cunningham MW, Jr., et al. Role of mitochondrial dysfunction and reactive oxygen species in mediating hypertension in the reduced uterine perfusion pressure rat model of preeclampsia. Hypertension. 2018;72(3):703–711. doi: 10.1161/HYPERTENSIONAHA.118.11290.

[146] Vishnyakova PA, Volodina MA, Tarasova NV, et al. Mitochondrial role in adaptive response to stress conditions in preeclampsia. Sci Rep. 2016;6(1):32410. doi: 10.1038/srep32410.

[147] Broady AJ, Loichinger MH, Ahn HJ, et al. Protective proteins and telomere length in placentas from patients with pre-eclampsia in the last trimester of gestation. Placenta. 2017;50:44–52. doi: 10.1016/j.placenta.2016.12.018.

[148] Holland OJ, Cuffe JSM, Dekker Nitert M, et al. Placental mitochondrial adaptations in preeclampsia associated with progression to term delivery. Cell Death Dis. 2018;9(12):1150. doi: 10.1038/s41419-018-1190-9.

[149] Rana S, Schnettler WT, Powe C, et al. Clinical characterization and outcomes of preeclampsia with normal angiogenic profile. Hypertens Pregnancy. 2013;32(2):189–201. doi: 10.3109/10641955.2013.784788.

[150] Redman CW, Sargent IL. Latest advances in understanding preeclampsia. Science. 2005;308(5728):1592–1594. doi: 10.1126/science.1111726.

[151] Ogge G, Chaiworapongsa T, Romero R, et al. Placental lesions associated with maternal underperfusion are more frequent in early-onset than in late-onset preeclampsia. J Perinat Med. 2011;39(6):641–652. doi: 10.1515/jpm.2011.098.