



# CEPHOTAXIME-ASSOCIATED ALLERGIC INTERSTITIAL NEPHRITIS AND MPO-ANCA POSITIVE VASCULITIS

Sandro Feriozzi, S. Feriozzi, A. Onetti Muda, V. Gomes, M. Montanaro, T. Faraggiana & E. Ancarani

**To cite this article:** Sandro Feriozzi, S. Feriozzi, A. Onetti Muda, V. Gomes, M. Montanaro, T. Faraggiana & E. Ancarani (2000) CEPHOTAXIME-ASSOCIATED ALLERGIC INTERSTITIAL NEPHRITIS AND MPO-ANCA POSITIVE VASCULITIS, Renal Failure, 22:2, 245-251, DOI: [10.1081/JDI-100100869](https://doi.org/10.1081/JDI-100100869)

**To link to this article:** <https://doi.org/10.1081/JDI-100100869>



Published online: 07 Jul 2009.



Submit your article to this journal [↗](#)



Article views: 589



View related articles [↗](#)



Citing articles: 3 View citing articles [↗](#)

## CLINICAL STUDY

# CEPHOTAXIME-ASSOCIATED ALLERGIC INTERSTITIAL NEPHRITIS AND MPO-ANCA POSITIVE VASCULITIS

S. Feriozzi, A. Onetti Muda\*, V. Gomes‡, M. Montanaro§,  
T. Faraggiana\*, and E. Ancarani

Nefrologia e Dialisi, †Anatomia Patologica, §Ematologia, Ospedale  
Belcolle, Viterbo, Italy; \*Dipartimento di Medicina Sperimentale e  
Patologia, Università La Sapienza, Roma, Italy

## ABSTRACT

We report a case of reversible acute renal failure after cephalexime treatment in a patient affected by non-Hodgkin lymphoma. Renal biopsy showed necrotizing vasculitis associated with eosinophil-rich interstitial inflammatory infiltrates and patchy infiltrates of CD20+ lymphoid cells. High serum p-ANCA titers were also detected. Drug withdrawal was closely related with recovery of renal function and disappearance of ANCA. Acute renal failure therefore represented a consequence of ANCA-mediated renal vasculitis and acute interstitial nephritis related to cephalexime treatment.

## INTRODUCTION

Detection of circulating antineutrophil cytoplasm antibodies (ANCA) has proved to be a powerful tool in clinical practice for the diagnosis of systemic vasculitis; antibodies against proteinase3 (cANCA) are mostly associated with Wegener granulomatosis while antibodies against myelo-

---

*Address for correspondence:* Sandro Feriozzi, M.D., Nefrologia e Dialisi, Ospedale Belcolle, Via Raniero Capocci, 13, 01100 VITERBO ITALY. Phone & Fax: + 39 0761 306110. E-mail: [ancarani@isa.it](mailto:ancarani@isa.it)

peroxidase (pANCA) occur more frequently in patients with different small-vessel necrotizing vasculitides (1,2).

Certain drugs (e.g., hydralazine or penicillin) are thought to be involved in the pathogenesis of vasculitis (3,4); the exact inducing mechanism(s) are not known, although an immuno-allergic pathway has been suggested (5,6). Recent demonstration of ANCA in the serum of patients with drug-induced vasculitis has provided additional data for an immunological link between vasculitis and drugs (7-11).

We report a patient affected by non-Hodgkin lymphoma who developed acute renal failure and high serum p-ANCA titers following therapy with cephalosporin; a renal biopsy showed acute necrotizing vasculitis associated with acute interstitial nephritis.

### CASE REPORT

A 65 year-old man was admitted to hospital because of cutaneous vesicular erythematous eruption localized to both legs and bilateral swelling of the neck. Cutaneous lesions had been present for six months and had shown periods of spontaneous remission.

Past medical history was unremarkable. Physical examination showed enlarged lymphnodes on both sides of the neck and armpits; hepatosplenomegaly was also present.

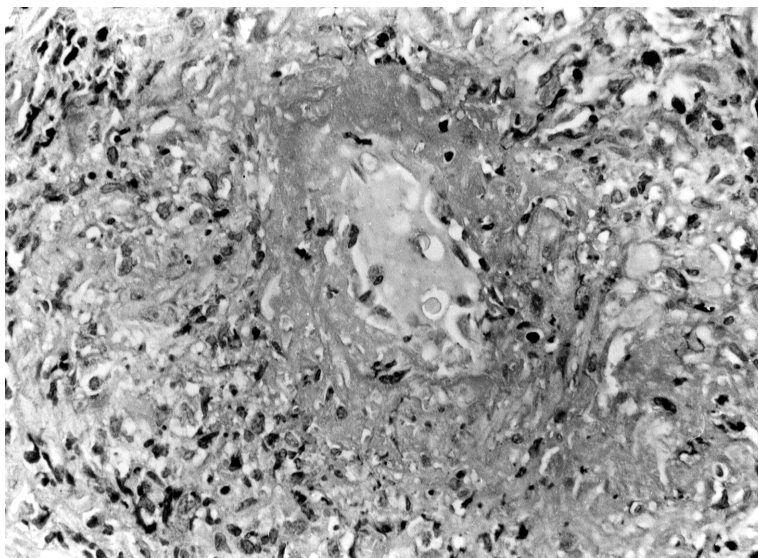
Laboratory values showed: ESR 112 mm/h, white blood cells 9.000 mmc, with a neutrophil count of 3.300 mmc, lymphocytes count of 4.200 mmc; red blood cells 4.100.000 mmc, Hb 12.3 g/dL, platelets 197.000, BUN 25 mg/dL, serum creatinine 1.2 mg/dL, serum protein 7.9 g/dL (albumin 45.5%,  $\alpha_1$  3.1,  $\alpha_2$  9.6%,  $\beta$  13.8%,  $\gamma$  27.9%); IgG 2150 mg/dL, IgA 525 mg/dL, IgM 223 mg/dL, C3 91 mg/dL, C4 13 mg/dL. Serum cryoglobulins were repeatedly absent. Urinalysis showed mild microhematuria (5-7 RBC/hpf); 24/h proteinuria was 0.8 g. Diuresis was 1400 mL/24h. Arterial blood pressure was 130/80 mmHg.

A total body CT scan revealed the presence of enlarged cervical, axillary, para-aortic, iliac and inguinal lymphnodes.

Bone marrow and cervical node biopsies displayed a B-cell non-Hodgkin lymphoma, small lymphocytic. A skin biopsy was characterized by non specific dermal inflammatory infiltrates.

On the 13<sup>th</sup> day after admission body temperature progressively increased up to 38,5°C; therapy with cephotaxime, 2g/die, was started in the same day with reduction of body temperature after 3 days.

During the following days the patient complained for nausea and fatigue; laboratory tests showed a progressive increase of serum creatinine up to 7.7 mg/dL at 6<sup>th</sup> day of antibiotic therapy, with a 24h diuresis of 800 mL.



**Figure 1.** Small caliber artery with acute vasculitis, showing necrosis of the media, detachment of endothelial cells and focal infiltrates of PMN. (Hematoxylin & Eosin;  $\times 350$ )

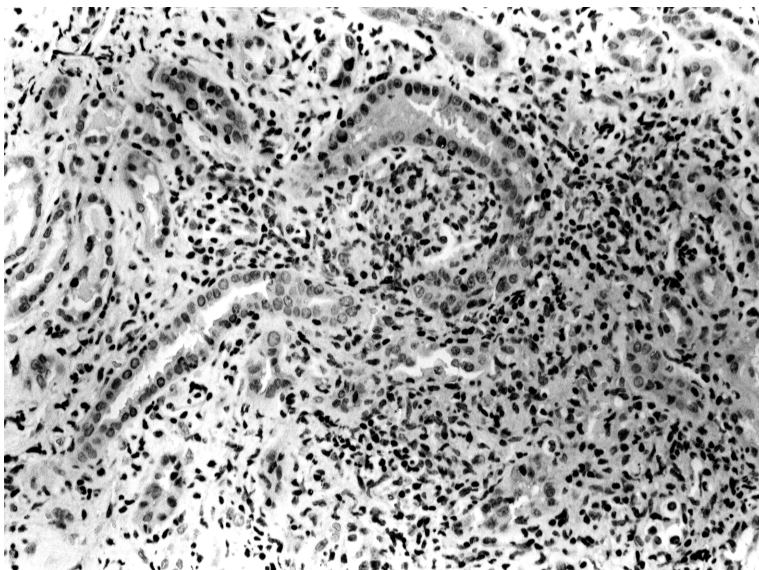
Arterial blood pressure was 120/80. Antimicrobial therapy was immediately withdrawn; ultrasound investigation demonstrated normal sized kidneys and a renal biopsy was performed on the 3<sup>rd</sup> day after withdrawal of antibiotic therapy.

Histological examination showed fibrinoid necrosis of small vessels (Fig.1) and diffuse inflammatory infiltrates of lymphocytes, monocytes, plasma cells and a significant number of eosinophils (Fig.2). In addition, patchy infiltrates made of small and medium-sized, non-cleaved, CD20+ lymphoid cells were also present (Fig.3). Glomeruli were normal and direct immunofluorescence was negative for IgG, IgA, IgM, C3, C1q and Fibrinogen. A diagnosis of allergic nephritis with necrotizing vasculitis and focal involvement by non-Hodgkin lymphoma was made. On the basis of the pathological diagnosis, tests for ANCA were performed, showing strong positivity for p-ANCA by indirect immunofluorescence (1:1200) and by ELISA (MPO-antibodies 72 EU/mL; normal range below 15 EU/mL).

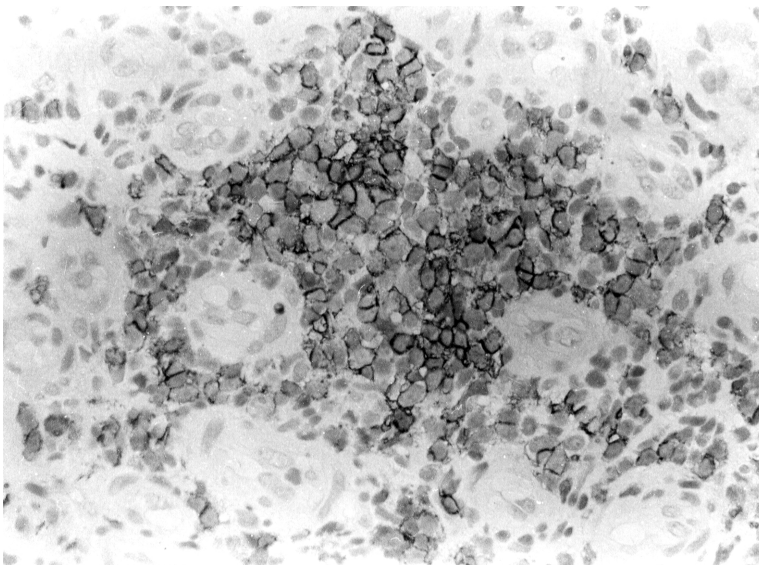
Withdrawal of antimicrobial therapy resulted in rapid clinical improvement, with complete recovery of renal function after 20 days from onset of renal failure. ANCA tests performed at this time were negative.

Therapy for lymphoma with cyclophosphamide, vincristine and prednisone (according to CVP regimen) (12) was started after 1 week from recovery of renal failure, and the patient was discharged.

At present, 15 months after onset of symptoms, the patient feels well and is being treated with low-dose steroids.



**Figure 2.** Small magnification micrograph of an area of interstitial nephritis. There is heavy infiltrates of lymphocytes, neutrophils and eosinophils; interstitium is expanded and tubules are destroyed. (Hematoxylin & Eosin;  $\times 175$ )



**Figure 3.** Patchy interstitial infiltrate of CD20+ lymphoid cells. (PAP technique; no counterstain.  $\times 350$ ).

## DISCUSSION

We describe a patient affected by low-grade non-Hodgkin lymphoma who developed acute renal failure after a short febrile episode treated with cephalexin. Renal biopsy showed small-vessel vasculitis, acute interstitial nephritis with eosinophils and mild renal interstitial involvement by lymphoproliferative disease; in addition, p-ANCA were detected in the patient's serum. Acute renal failure improved rapidly after withdrawal of cephalosporin treatment, with complete recovery of renal function.

In our case necrotizing vasculitis and interstitial nephritis could be due to lymphoma or immune reaction to cephalexin. Vasculitis may be a complication, although uncommon, of a lymphoproliferative disease: Wooten (13) suggested that patients with vasculitis should be screened for lymphoproliferative disease and Neuhauser (14) described acute renal vasculitis due to T-cell lymphoma in which biopsy findings were interpreted as Wegener granulomatosis, while autopsy revealed renal involvement by lymphoma. In addition, ANCA positivity in association with lymphoma has been reported, although only in a single case of intravascular malignant lymphomatosis of B-cell type (15).

Interstitial nephritis and, more rarely, vasculitis are known to be associated with antimicrobial treatment. In most cases it presents with acute renal failure accompanied with fever, eosinophilia and rash. Resolution usually occurs spontaneously after discontinuing the drug (4, 16).

In our case the strict temporal association between acute renal failure and cephalosporin administration, with rapid improvement of clinical picture after withdrawal of the drug, suggests that the latter is responsible for an immune-allergic renal disease (17).

The association between cephalosporin therapy and ANCA-associated renal vasculitis with interstitial nephritis has not been reported. However, acute interstitial nephritis in ANCA positive patients, with (7-11) or without (18-19) concomitant renal vasculitis is well established with several other drugs; in all cases withdrawal of drug was associated to rapid disappearance of ANCA (7-11, 18,19).

The exact pathogenetic mechanisms are not known; the possibility of reactive metabolite(s) of the drug acting as haptens in the formation of anti-MPO antibodies has been suggested (8,11,20). Renal involvement ranges from microhematuria and/or mild proteinuria to severe renal failure; the histological lesions vary from mild interstitial nephritis to severe diffuse extracapillary glomerulonephritis (7-11).

In conclusion, the clinical course, the rapid clinical improvement following drug withdrawal, associated with disappearance of ANCA from the serum and absence of serum cryoglobulins, seems to indicate a limited clinical event due to cephalexin administration. Acute renal

failure therefore may be a consequence of ANCA-mediated renal vasculitis and acute interstitial nephritis during cephotoxime treatment.

## REFERENCES

1. Falk RJ, Jennette JC: Anti-neutrophil cytoplasm antibodies with specificity for myeloperoxidase in patients with systemic vasculitis and idiopathic necrotizing and crescentic glomerulonephritis. *N Engl J Med* 318:1651-1657, 1988.
2. Jennette JC: Pathogenic potential of anti-neutrophil cytoplasm autoantibodies. *Lab Invest*; 2: 135-137, 1994.
3. Bernstein RM, Egerton-Vernon J, Webster J: Hydralazine-induced cutaneous vasculitis. *Br Med J*; 280:156-157, 1980.
4. Hannedouche T, Fillaste JP: Penicillin-induced hypersensitive vasculitides. *J Antimicrob Chemother* 20: 3-7, 1987.
5. Kleinknecht D, Kanfer A, Morel-Maroger L, Mèry JP: Immunologically mediated drug-induced acute renal failure. *Contrib Nephrol* 10:42-52, 1978.
6. Heptinstall RH: Polyarteritis nodosa, Wegener's syndrome, and other forms of vasculitis. In: Heptinstall RH (ed.); *Pathology of the kidney*, chap. 16 Little, Brown, Boston 1992, pp 1097-1162.
7. Jones BF, Mayor GAC: Crescentic glomerulonephritis in a patient taking penicillamine associated with antineutrophil cytoplasmic antibodies. *Clin Nephrol* 38:293, 1992.
8. Larsson GB, Langer L, Nassberger L. Thiazide-induced kidney damage with circulating antibodies against myeloperoxidase and cardiolipin. *J Intern Med* 233: 493-494, 1993.
9. Almroth G, Enestrom S, Hed J, Samuelsson I, Sjostrom P. Autoantibodies to leukocyte antigens in hydralazine associated nephritis. *J Intern Med* 231:37-42, 1992.
10. Dolman KM, Gans ROB, Vervaat TJ, Zevenbergen G, Maingay D, Nikkels RE, Donker AJM, von dem Borne AE, Goldschmeding RG: Vasculitis and anti-neutrophil cytoplasmic antibodies associated with propylthiouracil therapy. *Lancet* 342:651-652, 1993.
11. Shih DJ, Korbet SM, Rydel JJ, Schwartz MM: Renal vasculitis associated with ciprofloxacin. *Am J Kidney Dis*. 26:516-519, 1995.
12. Luce JK, Gamble JF, Wilson HE, Monto RW, Isaacs BL, Palmer RL, Coltman CA Jr, Hewlett JS, Gehan EA, Frei E 3d: Combined cyclophosphamide, vincristine, and prednisone therapy of malignant lymphoma. *Cancer* 28: 306-317, 1971.
13. Wooten MD, Jasin HE: Vasculitis and lymphoproliferative diseases. *Sem Arthritis Rheum* 26: 564-574, 1996.
14. Neuhauser Ts, Lancaster K, Haws R, Drehner D, Gulley ML, Lichy JH, Taubenberger JK: Rapidly progressive T cell lymphoma presenting as acute renal failure: case report and review of the literature. *Pediatr Pathol Lab Med* 17:449-460, 1997.
15. Al-Chalabi A, Sivakumaran M, Holton J, West KP, Wood JK, & Abbott RJ: A case of intravascular malignant lymphomatosis (angiotropic lymphoma)

- with raised perinuclear antineutrophil cytoplasmic antibody titres- a hitherto unreported association. *Clin Lab.Haemat* 16: 363-369, 1994.
16. Cameron JS: Allergic interstitial nephritis: clinical features and pathogenesis. *Q J Med* 66:97-115, 1988.
  17. Nguyen VD, Nagelberg H, Agarwal BN: Acute interstitial nephritis associated with cefotetan therapy. *Am J Kidney Dis* 3: 259-261, 1990.
  18. Singer S, Parry RG, Deodar HA, Barnes JN: Acute interstitial nephritis, omeprazole and antineutrophil cytoplasmic antibodies *Clin. Nephrol* 42:280, 1994.
  19. Kitahara T, Hiromura K, Sugawara M, Hirato J, sato S, Ueki K, Maezawa A, Yano S, Nojima Y, Naruse T: A case of cimetidina –induced acute tubulointerstitial nephritis associated with antineutrophil cytoplasmic antibody *Am J Kidney Dis* 33,2,1997.
  20. Cambridge G, Wallace H, Bernstein RM, Leaker B: Autoantibodies to myeloperoxidase and drug-induced systemic lupus erythematosus and vasculitis. *Br J Rheum* 33:109-114, 1994.