



Reprints & Permissions
Contact your librarian
For more information, visit
taylor & francis.com
or contact your librarian
For more information, visit
taylor & francis.com
or contact your librarian

ISSN: (Print) (Online) Journal homepage: informahealthcare.com/journals/doph20

Profile and Management Outcomes of Fireworks-Related Eye Injuries in Saudi Arabia: A 16-Year Retrospective Study

Huda AlGhadeer & Rajiv Khandekar

To cite this article: Huda AlGhadeer & Rajiv Khandekar (2021) Profile and Management Outcomes of Fireworks-Related Eye Injuries in Saudi Arabia: A 16-Year Retrospective Study, Clinical Ophthalmology, , 4163-4168, DOI: [10.2147/OPHTH.S333121](https://doi.org/10.2147/OPHTH.S333121)

To link to this article: <https://doi.org/10.2147/OPHTH.S333121>



© 2021 AlGhadeer and Khandekar.



Published online: 15 Oct 2021.



Submit your article to this journal [↗](#)



Article views: 136



View related articles [↗](#)



View Crossmark data [↗](#)




Citing articles: 4 View citing articles [↗](#)

Profile and Management Outcomes of Fireworks-Related Eye Injuries in Saudi Arabia: A 16-Year Retrospective Study

Huda AlGhadeer¹
Rajiv Khandekar²

¹Department of Emergency, King Khaled Eye Specialist Hospital, Riyadh, Saudi Arabia; ²Department of Research, King Khaled Eye Specialist Hospital, Riyadh, Saudi Arabia

→ Video abstract



Point your SmartPhone at the code above. If you have a QR code reader the video abstract will appear. Or use: <http://youtu.be/qmLRsuSnkvk>

Correspondence: Huda AlGhadeer
Department of Emergency, King Khaled
Eye Specialist Hospital, PO Box 7191,
Riyadh, 11462, Saudi Arabia
Tel +966 1 4821234 ext 2500
Fax +966 1 4821234 ext 3727
Email hghadeer@kkesh.med.sa

Background: Fireworks are a culturally significant part of celebrations in many parts of the world but can lead to blinding injuries.

Objective: To decipher the profile and management outcomes of fireworks-related eye injuries at a tertiary eye hospital in central Saudi Arabia.

Methods: This was a retrospective review of cases with fireworks-related eye injuries managed at our institution between 2003 and 2019. Demographic information, clinical features at presentation, mode of management, and visual outcome were evaluated at the last follow-up.

Results: A total of 155 eyes of 150 patients with a median age of 10 years [127 male (84.7%) and 69 (46%) right eyes, 76 (50.7%) left eyes, and 5 patients with bilateral injury] were enrolled for the study. Among the injured individuals, 59 (39.3%) were bystanders and 91 (60.7%) had ignited the fireworks. The fireworks included bangers (53; 35.3%), rockets in bottle (42; 28%), firecrackers (41; 27.3%). Closed globe injury (CGI) was the most common type of eye injury (100; 64.5% eyes) while Open globe injury (OGI) was noted in (55; 35.5% eyes). Management used for treatment included penetrating injury repair (55; 35.5%), lens removal/lens implant (51; 32.9%). Corrected distance visual acuity obtained after 6 months was 20/20 to 20/60 (74; 47.7%), 20/70 to 20/200 in (31; 20%), <20/200 to 20/400 in (9; 5.8%) and <20/400 in (41; 26.5%) eyes. Treatment was able to restore vision and salvage blindness in 50 (32.3%) eyes.

Conclusion: Mainly males were found to suffer from fireworks-related eye injuries and the main fireworks responsible for them were bangers. Visual disability remained in one-third of the treated patients.

Keywords: fireworks, injuries, ocular trauma, visual loss

Introduction

Fireworks are a culturally significant part of celebrations in many parts of the world.¹ It was estimated by the United States Consumer Product Safety Commission (CPSC) that nearly 10,500 individuals (3.3 per 100,000) underwent treatment at emergency department of hospitals for injuries related to fireworks in year 2014. This rate of affected individuals has remained relatively stable since year 1999.^{2,3} Fireworks originated in ancient China which contained combustible chemicals that caused explosion or spectacular effects.⁴ Across Europe, ocular damage is reported in 21.8% cases (16% to 45%) of all the fireworks-related injuries.⁵ It was reported in a study conducted in USA that ocular injuries

contributed to nearly 31% of all the fireworks-related trauma during Independence Day celebrations.⁶ Wisse et al⁵ reported that the use of fireworks in developing and developed countries contributed to 22% of total eye injuries. Overall, it could be stated that fireworks-related trauma is the main reason for visual disability.⁷

To the best of our knowledge, data about the epidemiology of fireworks-related ocular injuries in Saudi Arabia is limited. In this study, we are presenting the epidemiology of fireworks-related ocular injuries, causes and their management outcomes at a tertiary eye hospital in central Saudi Arabia over a time period of 16 years.

Materials and Methods

This retrospective study was carried out at our institution. The Hospital's Institutional Review Board approved this study and it adhered to the tenets of the Declaration of Helsinki. A chart review was done for the patients who visited the hospital during year 2003 to 2019 with the complaint of ocular injuries caused by the fireworks from 2003 to 2019 (16 years). Written informed consent, including consent to publish, was obtained from all participants. The demographic profile of patients including age at the time of management, gender, laterality (right, left or both eyes), type of injury and type of fireworks were recorded. It was also recorded that person who got injured was an active participant in firework ignition or was a bystander. A comprehensive ophthalmic examination was performed using slit lamp biomicroscopy (Topcon Corp., Tokyo, Japan) at the initial presentation of the individual as well as on follow-up visits. The posterior segment was examined using indirect binocular ophthalmoscope (Keller, USA). Ocular B-scan ultrasonography, ultrasound biomicroscopy and tonometry (using Tonopen Medtronic plc., Dublin, Ireland) were performed only if the globe was not perforated. Orbital computed tomography (CT) scan was performed to evaluate the presence/absence of intraocular foreign body (IOFB). All patients who sustained open globe injuries underwent imaging of the eye and orbit before any intervention to rule out retention of any foreign bodies. The extent of ocular damage was noted, and the details of management were recorded. Surgical intervention, when indicated, was performed within 24 hours of presentation. All patients were classified based on Ocular Trauma Classification System (OTCS).⁸ Since our institute is an ophthalmic specialized center, all patients presented with isolated eye injuries were treated here and for the associated body injuries, they were treated at another general hospital.

Uncorrected and corrected distance visual acuity (UDVA and CDVA, respectively) was tested with a Snellen chart or Cardiff acuity cards or finger counting at the time of initial presentation and after management. Poor visual outcome was defined as CDVA <20/200 and unilateral blindness as CDVA <20/400 in the injured eye. The visual impairment grades defined by the World Health Organization were adopted in our study.⁹

Microsoft office excel 2010 was used for collecting data. Univariate analysis was performed using Statistical Package for Social Sciences (SPSS 25) (IBM Corp., Armonk, NY, USA). Normally distributed quantitative variables were expressed as the mean \pm standard deviation (SD). Presentation of qualitative variables was done as frequencies and percentage proportion. For subgroup analysis validation of continuous variables, we performed Student's *t*-test, and a two-sided *P* value was calculated. *P*<0.05 was considered statistically significant.

Results

A total 155 eyes of 150 individuals with ocular injury due to fireworks were enrolled for the study. Their median age was 10 years (IQR 7; 14). Of all the recruited patients, 127 (84.7%) were male and 23 females. Bilateral injury was noted in 5 patients. Sixty-nine (46%) patients had the involvement of right eye in the injury.

Among the type of fireworks which caused injury, as recalled by the patients, bangers were the most common causing injury in 53 individuals (35.3%) followed by rockets placed in bottle in 42 (28%), firecrackers in 41 (27.3%), and unknown in 14 (9.3%). As many as 59 (39.3%) patients were bystanders and 91 (60.7%) patients were involved in igniting the fireworks at the time of ocular injury. Diagnosis of all the ocular injuries caused by fireworks is summarized in Table 1. The most common injuries included corneal/scleral/corneoscleral laceration in 35.5% eyes (Figure 1) and traumatic cataract in 33.5% eyes (Figure 2). Classification of fireworks-related ocular injuries is showing in Table 2. Type of surgical management used in ocular injuries has been mentioned in Table 3.

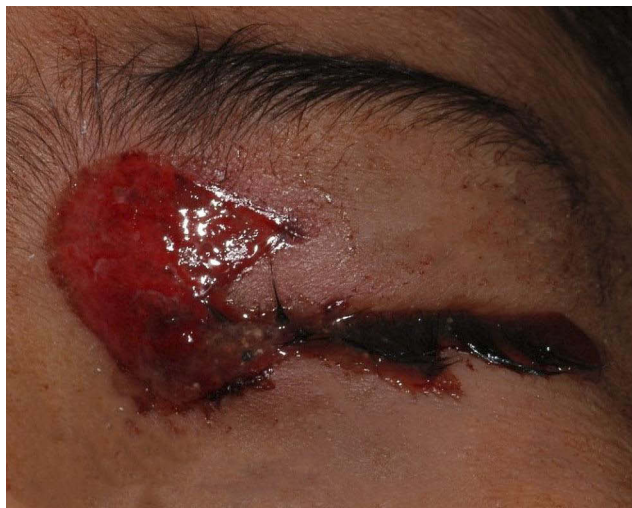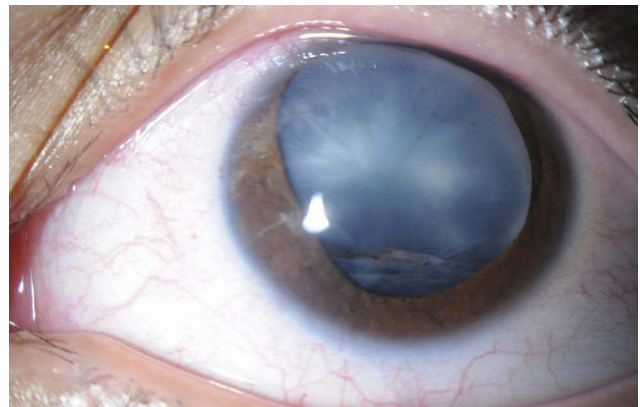
Poor visual outcome was defined as vision <20/200 in the injured eye. After either surgical or medical intervention, 74 (47.7%) eyes had good visual outcome (20/40 or better). The prevalence of unilateral blindness in our study was 32.2% out of 47% eyes with <20/200 before management. We were able to reduce severe visual impairment to 32.3%.

Table 1 Diagnosis of Fireworks-Related Ocular Injuries

Anterior Segment Trauma	Number	Percentage
Burns to the eyelids	10	6.4
Eyelid laceration	4	2.6
Orbital fracture	1	0.6
Conjunctival wound/burn	6	3.9
Corneal abrasion	23	14.8
Conjunctival/Corneal foreign body	10	6.4
Limbal Stem cell deficiency	16	10.3
Hyphema	36	23.2
Corneal/Sclera/Corneoscleral laceration	55	35.5
Traumatic cataract	52	33.5
Dislocated lens	19	12.2
Iridodialysis	13	8.4
Angle recession/secondary glaucoma	35	22.6
Lens subluxation	8	5.1
Traumatic iritis	11	7.1
Posterior Segment Trauma	Number	Percentage
Vitreous hemorrhage	16	10.3
Optic nerve contusion	5	3.2
Retinal detachment	15	9.7
Choroidal detachment	3	1.9
Comotio retinae	6	3.9
Traumatic macular hole	3	1.9
Intraocular foreign body	22	14.2
Endophthalmitis	2	1.3
Choroidal ruptures	1	0.6

Discussion

Based on the results obtained from this study for the patients with ocular injuries due to fireworks, it was

**Figure 1** Severe eye trauma with eyelid laceration and open globe injury in a child with firework injury.**Figure 2** Subluxated cataractous lens in the eye of a person having a firework injury.

found that young male children are predominantly affected by it and mainly uniocular trauma occurs. Bangers and rockets were main types of fireworks causing ocular injuries and among clinical diagnosis, corneoscleral lacerations and traumatic cataract were the main ocular presentations. The most common cause for these injuries was ignition of the fireworks, and it was found that four in the ten affected patients were bystanders. Nearly half of the affected individuals had normal functional vision six months after management. Therefore, it is evident that prompt and standard intervention could reduce blindness by one third.

Table 2 Classification of Fireworks-Related Ocular Injuries

Type of Injury	N= 155 Eyes	Percentage
Closed globe injury (CGI)	100	64.5%
Open globe injury (OGI)	55	35.5%

Abbreviations: CGI, closed globe injury; OGI, open globe injury.

Table 3 Surgical Management of Eyes with Fireworks Injuries

Surgical Management	Number	Percentage
Corneal/Scleral/Corneoscleral repair	55	35.5
Vitrectomy	19	12.2
Cataract extraction and IOL insertion	51	32.9
Repair of eyelid	4	2.6
Repair of orbital fracture	1	0.6
Trabeculectomy	4	2.6
Enucleation	9	5.8
Anterior chamber washout	1	0.6
Amniotic membrane transplantation	19	12.2
Corneal transplantation	2	1.3
Removal of IOFB	18	11.6

Abbreviations: IOL, intraocular lens; IOFB, intraocular foreign body.

Studies related to ocular injuries and outcomes of standard management are not new. However, studies based on fireworks-related ocular injuries and outcomes of management in Arabian population is unique. With strict laws preventing fireworks in Saudi Arabia, availability and unsupervised usage is a matter of concern. Various awareness campaigns of the hazards of fireworks-related ocular injuries through different media, social networks were performed to raise public awareness. The findings of the present study indicate that additional policies regarding use of fireworks are required to reduce the incidences of visual morbidity in children (and adults).

Fireworks-related Ocular injuries are mainly common during occasions, such as Diwali in India, the spring festival in China and Eid al-Fitr celebration in Islamic countries like Malaysia.^{10–13} In Saudi Arabia, Al-Qattan and Al-Tamimi have reported hand burns due to fireworks.¹⁴ Their study observations have indicated that wherever fireworks related injuries occur, there is a strong possibility of ocular injuries, and it needs to be evaluated.

In our study, half of the injured children were younger than 10 years of age. This indicates that children are more vulnerable to ocular trauma due to fireworks. This observation concurs with previous studies.^{15,16} In USA, 10 to 20 years old comprised of one-third of the injured children.¹⁷ This observation has been attributed to the lack of supervision, little experience in handling fireworks, more risk-taking behavior, and lower ability to respond to the dangerous hazards. Overall data indicates that there is a need for educating children regarding the dangers that fireworks pose, and implementation of this education at an earlier school age.

In our study more males than females had fireworks-related ocular injuries which is consistent with the previously available literature^{4,11,18}. The male preponderance in the frequency and severity of the injury may be attributed to increased risk taking behavior amongst males. This highlights a need for awareness and prevention programs that targets young males who appear to be at greater risk.

In our study, 39.3% of injured people were bystanders and received ocular related-fireworks injury indicating the possible threat to the gathering of observers by the fireworks. Hence, bystanders watching fireworks must also pay adequate attention while watching fireworks and take appropriate measures to shield themselves as warranted. This finding of ours concurs with previously reported studies.^{19,20} On the contrary, the percentage of bystanders was found to be quite high in a study from Nigeria.²¹

Data from our study suggested that the most common fireworks causing the injury were bangers, followed by rockets placed in bottles.

One of the most dangerous fireworks causing serious injuries include bottle rockets, which can fly erratically and cause major harm to the bystanders. More often the bottles and cans used for launching these rockets explode and shower pieces of glass and metal which could cause serious injuries.²² Mortar-type fireworks were reported as the reason for firework-related injuries in one fourth of the patients as reported by Chang et al.⁶

Of the clinical diagnosis caused by fireworks injuries, each corneoscleral laceration and traumatic cataract contributed for one third of the total ocular injuries noted in this study. Chang et al.⁶ reported corneal abrasions, hyphema and various eyelid injuries to be the most common ocular injuries. When comparing injuries to the posterior segment of eye, we noted the most common were intraocular foreign body (IOFB) (14.2%) and vitreous hemorrhage (10.3%). The incidence of posterior segment injuries reported in the current study is higher than those reported by Qi et al.¹⁶ The higher velocity projectiles could damage deeper ocular structures, and this might be the possible reason for these differences between studies.

It was observed in this study that patients sustaining severe trauma needed multiple interventions along with follow-up for long duration as well as repetitive rehabilitative surgery, even after years of trauma related to fireworks. The corneoscleral repair in one-third of patients was performed within 6 to 48 hours. Reconstruction of eyelids or orbit and cataract surgeries were interventions undertaken over time as elective procedures. Fireworks-related injuries can cause permanent functional or visual disabilities.^{14,23} Therefore, standard operating procedures to ocular injuries due to fireworks should include early ophthalmic referral and examination for urgent intervention.

In the current study, nearly half of the injured eyes had a normal functional vision post intervention. One third of the eyes had unilateral blindness after intervention compared to nearly half at presentation. Cumulative data suggests that enrolled patients experienced improvement in their visual acuity post treatment, however a significant number of injuries led to permanent visual loss as well. This good outcome in the form of restoration of normal vision was associated with better initial CDVA, closed globe injury, absence of retinal detachment and absence of IOFB. Significant improvement in visual acuity was found to be associated with early intervention.

We further observed that open globe injury and IOFB led to extremely poor visual outcome. Open globe injury, poor initial visual acuity at presentation, IOFB, retinal detachment, and development of endophthalmitis are previously reported risk factors responsible for poor visual outcomes even after interventions following fireworks-related ocular injuries.^{22,24,25} Patients with open globe injuries and those with retained IOFB carry a guarded prognosis.

Limitations

There are some limitations in our study. This being a retrospective data review, data loss is an inherent limitation. Patients with minor injuries who were treated and discharged quickly were not documented, and hence, we could have underestimated the incidences and over-represented the severity of ocular trauma due to fireworks.

Conclusions

Fireworks usage is associated with preventable ocular injuries. Outcomes of this study could be used as evidence for increasing awareness among public regarding fireworks-related injuries and also develop some public policies for regulating the use of fireworks.^{26–28} Based on the data of this study, strict implementation of existing laws for the import, production of fireworks and quantity of explosives is advocated. Future prevention campaigns and regulation should include the welfare of bystanders and children, not just those lighting the fireworks. Keeping in view, the poor prognosis for visual function, these injuries deserve proper attention.

Abbreviations

CGI, closed globe injury; OGI, open globe injury; CT, computed tomography; IOFB, intraocular foreign body; CDVA, corrected distance visual acuity; IOL, intraocular lens.

Statement of Ethics

The local ethics committee of the King Khaled Eye Specialist Hospital approved the protocol and it adhered to the tenets of the Declaration of Helsinki. The nature of the study and its possible consequences were explained to study participants. All participants have given their written informed consent to participate in this study.

Acknowledgment

We would like to thank the research coordinator Mr. Faisal Al Hamidi for his invaluable help in this study.

Author Contributions

Both authors made a significant contribution to the work reported, whether that is in the conception, study design, execution, acquisition of data, analysis, and interpretation, or in all these areas; took part in drafting, revising or critically reviewing the article; gave final approval of the version to be published; have agreed on the journal to which the article has been submitted; and agree to be accountable for all aspects of the work.

Funding

This manuscript did not receive any funding.

Disclosure

No conflict of interest was declared by the authors and the authors declared that this study received no financial support. The authors report no financial interests in terms of the presented study.

References

1. Read DJ, Bradbury R, Yeboah E. Firework-related injury in the top end: a 16-year review. *ANZ J Surg.* 2017;87(12):1030–1034. doi:10.1111/ans.14182
2. United States Consumer Product Safety Commission. Fireworks-related deaths, emergency department-treated injuries, and enforcement activities during 2014 in fireworks annual report 2014. Available from: https://www.cpsc.gov/s3fs-public/Fireworks_Report_2014_0.pdf. Accessed July 26, 2019.
3. Sandvall BK, Jacobson L, Miller EA, et al. Fireworks type, injury pattern, and permanent impairment following severe fireworks-related injuries. *Am J Emerg Med.* 2017;35(10):1469–1473. doi:10.1016/j.ajem.2017.04.053
4. Bagri N, Saha A, Chandelia S, et al. Fireworks injuries in children: a prospective study during the festival of lights. *Emergency Med Australasia.* 2013;25(5):452–456.
5. Wisse RP, Bijlsma WR, Stilma JS. Ocular firework trauma: a systematic review on incidence, severity, outcome and prevention. *Br J Ophthalmol.* 2010;94(12):1586–1591. doi:10.1136/bjo.2009.168419
6. Chang IT, Prendes MA, Tarbet KJ, Amadi AJ, Chang SH, Shaftel SS. Ocular injuries from fireworks: the 11-year experience of a US level I trauma center. *Eye.* 2016;30(10):1324–1330. doi:10.1038/eye.2016.104
7. Frimmel S, de Faber JT, Wubbels RJ, Kniestedt C, Paridaens D. Type, severity, management and outcome of ocular and adnexal firework-related injuries: the Rotterdam experience. *Acta Ophthalmol.* 2018;96(6):607–615. doi:10.1111/aos.13711
8. Pieramici DJ, Sternberg P, Aaberg TM, Bridges WZ, Capone A, Cardillo JA. A system for classifying mechanical injuries of the eye (globe). The ocular trauma classification group. *Am J Ophthalmol.* 1997;123:820–831. doi:10.1016/S0002-9394(14)71132-8

9. World Health Organization. International statistical classification of diseases and related health problems: tenth revision. Geneva; 1992.
10. Arya SK, Malhotra S, Dhir SP, Sood S. Ocular fireworks injuries. Clinical features and visual outcome. *Indian J Ophthalmol.* 2001;49(3):189–190.
11. Rashid RA, Heidary F, Hussein A, et al. Ocular burns and related injuries due to fireworks during the Aid il Fitri celebration on the East Coast of the Peninsular Malaysia. *Burns.* 2011;37(1):170–173.
12. Mansouri MR, Mohammadi SF, Hatef E, et al. The persian wednesday eve festival “Charshanbe-Soori” fireworks eye injuries: a case series. *Ophthalmic Epidemiol.* 2007;14(1):17–24. doi:10.1080/09286580600878836
13. Sacu S, Ségur-Eltz N, Stenng K, Zehetmayer M. Ocular firework injuries at New Year's Eve. *Ophthalmologica.* 2002;216(1):55–59. doi:10.1159/000048298
14. Al-Qattan MM, Al-Tamimi AS. Localized hand burns with or without concurrent blast injuries from fireworks. *Burns.* 2009;35(3):425–429. doi:10.1016/j.burns.2008.06.015
15. Venkatesh R, Gurav P, Tibrewal S, et al. Appraising the spectrum of firework trauma and the related laws during Diwali in North India. *Indian J Ophthalmol.* 2017;65(2):140–143. doi:10.4103/ijo.IJO_527_16
16. Qi Y, Zhu Y. Prognostic value of an ocular trauma score in ocular firecracker trauma. *J Burn Care Res.* 2013;34(3):e183–6. doi:10.1097/BCR.0b013e3182676ce0
17. Moore JX, McGwin G Jr, Griffin RL. The epidemiology of firework-related injuries in the United States: 2000–2010. *Injury.* 2014;45(11):1704–1709. doi:10.1016/j.injury.2014.06.024
18. Kon M. Firework injuries to the hand. *Annales de Chirurgie de la Main et du Membre Supérieur.* 1991;10(5):443–447.
19. Wang C, Zhao R, Du WL, Ning FG, Zhang GA. Firework injuries at a major trauma and burn center: a five-year prospective study. *Burns.* 2014;40(2):305–310. doi:10.1016/j.burns.2013.06.007
20. John D, Philip SS, Mittal R, John SS, Paul P. Spectrum of ocular firework injuries in children: a 5-year retrospective study during a festive season in Southern India. *Indian J Ophthalmol.* 2015;63(11):843–846. doi:10.4103/0301-4738.171966
21. Apakama AI, Anajekwu CC. Ocular fireworks injuries in Eastern Nigeria: a 3-year review. *Nigerian J Surg.* 2019;25(1):42–44. doi:10.4103/njs.NJS_29_15
22. Chan WC, Knox FA, McGinnity FG, Sharkey JA. Serious eye and adnexal injuries from fireworks in Northern Ireland before and after lifting of the firework ban-an ophthalmology unit's experience. *Int Ophthalmol.* 2004;25(3):167–169. doi:10.1007/s10792-004-1958-z
23. Knox FA, Chan WC, Jackson AJ, Foot B, Sharkey JA, McGinnity FG. A British ophthalmological surveillance unit study on serious ocular injuries from fireworks in the UK. *Eye.* 2008;22(7):944–947. doi:10.1038/sj.eye.6702778
24. Malik A, Bhala S, Arya SK, Sood S, Narang S. Five-year study of ocular injuries due to fireworks in India. *Int Ophthalmol.* 2013;33(4):381–385. doi:10.1007/s10792-013-9714-x
25. Singh DV, Sharma YR, Azad RV. Visual outcome after fireworks injuries. *J Trauma Acute Care Surg.* 2005;59(1):109–111. doi:10.1097/01.TA.0000172643.61750.AF
26. Nizamoglu M, Frew Q, Tan A, et al. The ten-year experience of firework injuries treated at a UK regional burns & plastic surgery unit. *Ann Burns Fire Disasters.* 2018;31(1):13–16.
27. Rad EH, Kouchakinezhad-Eramsadati L, Mohtsham-Amiri Z, Davoudi-Kiakalayeh A, Yousefzadeh-Chabok S. Effectiveness of an educational program on decreasing burns and injuries in Persian festival of fire: a burden of diseases approach. *Burns.* 2019;45(2):466–470. doi:10.1016/j.burns.2018.07.011
28. Billock RM, Chounthirath T, Smith GA. Pediatric firework-related injuries presenting to United States Emergency Departments, 1990–2014. *Clin Pediatr.* 2017;56(6):535–544. doi:10.1177/0009922816664063

Clinical Ophthalmology

Publish your work in this journal

Clinical Ophthalmology is an international, peer-reviewed journal covering all subspecialties within ophthalmology. Key topics include: Optometry; Visual science; Pharmacology and drug therapy in eye diseases; Basic Sciences; Primary and Secondary eye care; Patient Safety and Quality of Care Improvements. This journal is indexed on PubMed

Submit your manuscript here: <https://www.dovepress.com/clinical-ophthalmology-journal>

Dovepress

Central and CAS, and is the official journal of The Society of Clinical Ophthalmology (SCO). The manuscript management system is completely online and includes a very quick and fair peer-review system, which is all easy to use. Visit <http://www.dovepress.com/testimonials.php> to read real quotes from published authors.