



Erratum

To cite this article: (2010) Erratum, Medical Mycology, 48:3, 560-560, DOI: [10.3109/13693781003715229](https://doi.org/10.3109/13693781003715229)

To link to this article: <https://doi.org/10.3109/13693781003715229>



Published online: 06 Apr 2010.



Submit your article to this journal [↗](#)



Article views: 109



View related articles [↗](#)

Erratum

Due to a production error, the cover image and figure legend of issue 48:2 did not correspond to each other. Therefore, to correct this situation, please find below the appropriate photomicrograph from the paper by Najafzadeh *et al.* which appeared in the same issue of the journal.

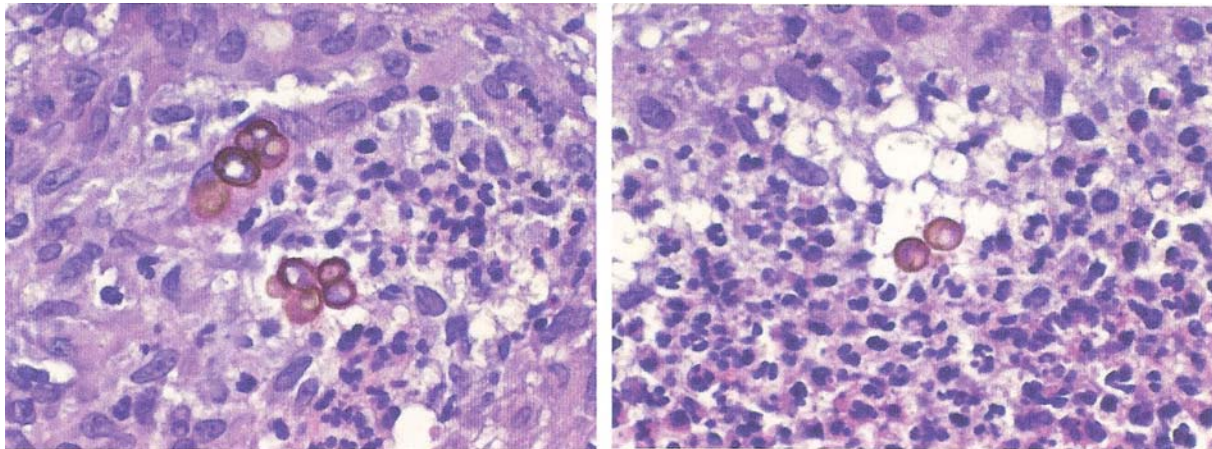


Fig. 1 Sclerotic bodies found through histopathological examination of biopsy samples (hematoxylin-eosin stain) from a case of chromoblastomycosis caused by *Fonsecaea monophora* as reported by Najafzadeh *et al.*