



Atypical femoral fractures bilaterally in a patient receiving denosumab

Efstathios Drampalos, George Skarpas, Nikos Barbounakis & Ioannis Michos

To cite this article: Efstathios Drampalos, George Skarpas, Nikos Barbounakis & Ioannis Michos (2014) Atypical femoral fractures bilaterally in a patient receiving denosumab, Acta Orthopaedica, 85:1, 3-5, DOI: [10.3109/17453674.2013.854668](https://doi.org/10.3109/17453674.2013.854668)

To link to this article: <https://doi.org/10.3109/17453674.2013.854668>



Copyright: © Nordic Orthopaedic Federation



Published online: 31 Oct 2013.



Submit your article to this journal [↗](#)



Article views: 1692



View related articles [↗](#)



View Crossmark data [↗](#)



Citing articles: 7 View citing articles [↗](#)

Atypical femoral fractures bilaterally in a patient receiving denosumab – a case report

Efstathios Drampalos¹, George Skarpas², Nikos Barbounakis², and Ioannis Michos²

¹Department of Orthopedics, Broomfield Hospital, Essex, UK; and ²Orthopedic Department, Asklepieion Voulas Hospital, Athens, Greece.

Correspondence: edrampalos@yahoo.gr

Submitted 13-06-22. Accepted 13-08-12

We present a case of bilateral low-energy femoral shaft fractures over a 1-year period in a woman after discontinuation of long-term alendronate therapy and initiation of treatment with denosumab.

A 73-year-old woman with diabetes mellitus and an 8-year history of post-menopausal osteoporosis presented to the emergency department in June 2011 with a spontaneous left femur fracture. It was 3 weeks after the discontinuation of an 8-year therapy with vitamin D supplement and 70 mg alendronate weekly, and 1 week after the first subcutaneous injection of denosumab. Radiographs revealed a transverse femoral shaft fracture with lateral cortical hypertrophy and medial spiking (Figure 1).

The fracture was stabilized with a cephalomedullary nail. Routine blood investigations were within normal range and myeloma was excluded. Bone densitometry revealed an increase in bone density relative to baseline values before the initiation of alendronate therapy, but the T-score of at least 1

site was still in the osteoporotic range (femoral neck T-score: –2.95). 5 months postoperatively, the fracture had healed with callus formation.

1 year after the first fracture, the patient sustained a similar atypical fracture of the right femoral shaft (Figure 2) and she described mild, diffuse pain in the thigh during the previous 6–7 months. She was still on treatment with denosumab 12 months after the first injection (she had received 3 injections of denosumab at 6-month intervals). This fracture was also stabilized with a cephalomedullary nail and a pathological fracture was excluded.

This fracture also healed in 5 months with callus formation (Figure 3). In view of reports linking this pattern of femoral shaft fractures to long-term alendronate therapy (Neviaser et al. 2008) and considering the anti-resorptive mechanism of action of the denosumab, treatment with teriparatide (20 µg subcutaneously once a day) and vitamin D was commenced and denosumab was stopped.

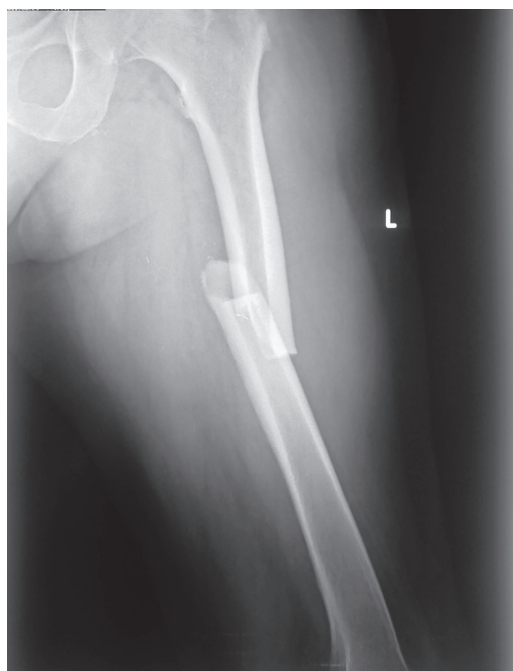

Figure 1. The patient's left femur at the time of the first fracture. A transverse femoral shaft fracture with lateral cortical hypertrophy and medial spiking.

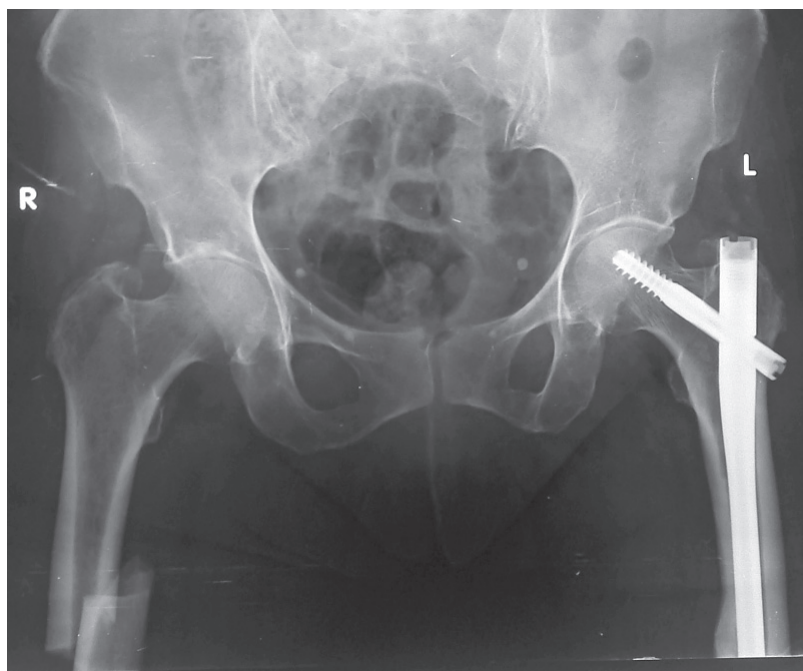


Figure 2. Both femurs at the time of the right femoral shaft fracture.

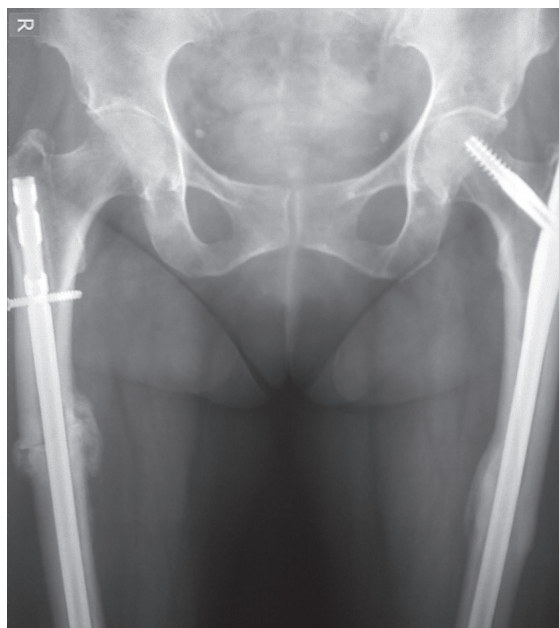


Figure 3. Anteroposterior radiograph of both femurs 5 months after the second operation, showing healing of the fracture with callus formation.

Discussion

In recent years, several clinical case reports and case reviews have described atypical femoral fractures (AFFs) in patients receiving treatment with bisphosphonates. It has been hypothesized that suppression of bone turnover leads to accumulation of microdamage and an increased risk of AFF (Shane et al. 2013) with prolonged bisphosphonate exposure.

The American Society for Bone and Mineral Research (ASBMR) task force described major and minor defining features of AFF (Shane et al. 2013). Our case had all of the major features: the location was the subtrochanteric region, the fracture was transverse, there was no trauma, there was a medial spike, there was no comminution, and there was a periosteal reaction of the lateral cortex. Regarding the minor features, there was cortical thickening, prodromal pain, and bilaterality. We have found only 1 reported case of an unusual subtrochanteric fracture in a patient on denosumab (Paparodis et al. 2013).

Denosumab offers an alternative approach to the treatment of osteoporosis. It is a fully human monoclonal antibody to the receptor activator of nuclear factor- κ B ligand (RANKL) that prevents the interaction of RANKL with RANK (its receptor on osteoclasts and their precursors), thereby blocking the formation, function, and survival of osteoclasts (Cummings et al. 2009). The “study of transitioning from alendronate to denosumab” (STAND) evaluated the impact on safety, BMD, and bone remodeling in patients switching from alendronate to denosumab (Kendler et al. 2010) and contributed to FDA approval of denosumab.

The risk of AFFs appears to increase in parallel with the duration of bisphosphonate exposure, from 1.8 cases per 10^5 users per year of exposure for the first 2 years, to 113 cases per 10^5 users per year at 8 years of bisphosphonate use (Kendler et al. 2010). Our patient developed her first fracture after 8 years of alendronate use. Furthermore, according to Schilcher et al. (2011), after drug withdrawal, bisphosphonate-associated risk diminishes by 70% per year since the last use. The first fracture in our patient happened just 3 weeks after last use, so there could be a strong association with bisphosphonates and a causal relationship is highly likely. The second fracture happened 1 year and 3 weeks after the last use of bisphosphonate, so in this case the causal relationship is unlikely to exist.

Our patient had received the first injection of denosumab 1 week before the first fracture and then she received 2 other doses before the second fracture (to the right femur) i.e. she had subcutaneous administration of 60 mg denosumab every 6 months. The limited time of exposure to denosumab before the first fracture makes it unlikely that this fracture was causally related to the effects of denosumab, but by the time of the second fracture a year later the patient had been exposed to 3 doses of denosumab.

The efficacy and safety of pharmacological treatment (e.g. teriparatide, strontium ranelate, denosumab) for patients with osteoporosis remains an area for research, but since over-suppression of bone turnover is implicated, we preferred to stop treatment with denosumab and to start our patient on teriparatide. Teriparatide (PTH 1-34: recombinant human parathyroid hormone (1–34)) is a bone anabolic agent that reduces the risk of vertebral and non-vertebral fractures in post-menopausal women with osteoporosis (Langdahl et al. 1968).

Our case does not provide conclusive evidence of a causal relationship between treatment with denosumab and this unusual type of fracture. It does, however, clearly illustrate the notable occurrence of bilateral femoral fractures, with many features in common with bisphosphonate-associated atypical femoral fractures, in a patient receiving the potent anti-resorptive agent denosumab.

ED wrote and revised the manuscript, GS evaluated the radiological findings, NB followed the patient, and IM coordinated and revised the manuscript.

No competing interests declared.

Cummings S R, San Martin J, McClung M R, Siris E S, Eastell R, Reid I R, Delmas P, Zoog H B, Austin M, Wang A, Kutilek S, Adami S, Zancetta J, Libanati C, Siddhanti S, Christiansen C; FREEDOM Trial. Denosumab for prevention of fractures in postmenopausal women with osteoporosis. *N England J Med* 2009; 361:756–65.

Kendler D, Roux C, Benhamou C, et al. Effects of denosumab on bone mineral density and bone turnover in postmenopausal women transitioning from alendronate therapy. *J Bone Miner Res* 2010; 25: 72–81.

- Langdahl B L, Rajzbaum G, Karras F J D, Ljunggren Ö, Lems W F, Fahrleitner-Pammer A, Walsh J B, Barker C, Kutahov A, Marin F. Reduction in fracture rate and back pain and increased quality of life in postmenopausal women treated with teriparatide: 18-month data from the European Forsteo Observational Study (EFOS). *Calcif Tissue Int* 2009; 85 (6): 484-93.
- Neviaser A S, Lane J M, Lenart B A, Edobor-Osula F, Lorch D G. Low-energy femoral shaft fractures associated with alendronate use. *J Orthop Trauma* 2008; 22: 346-50.
- Paparodis R, Buehring B, Pelley E, Binkley N. A case of an unusual subtrochanteric fracture in a patient receiving denosumab. *Endocr Pract* 2013; 21: 1-17. [Epub ahead of print].
- Schilcher J, Michaëlsson K, Aspenberg P. Bisphosphonate use and atypical fractures of the femoral shaft. *N Engl J Med* 2011; 364 :1728-37.
- Shane E, Burr D, Abrahamsen B et al. Atypical subtrochanteric and diaphyseal femoral fractures: Second report of a task force of the American Society for Bone and Mineral Research. *J Bone Miner Res* 2013. doi: 10.1002/jbmr.1998. [Epub ahead of print].