



Incomplete periacetabular acetabuloplasty

A one-stop procedure for developmental dysplasia of the hip

Belen Carsi, Sariyah Al-Hallao, Karim Wahed, Jonathan Page & Nicholas M P Clarke

To cite this article: Belen Carsi, Sariyah Al-Hallao, Karim Wahed, Jonathan Page & Nicholas M P Clarke (2014) Incomplete periacetabular acetabuloplasty, Acta Orthopaedica, 85:1, 66-70, DOI: [10.3109/17453674.2014.886030](https://doi.org/10.3109/17453674.2014.886030)

To link to this article: <https://doi.org/10.3109/17453674.2014.886030>



Copyright: © Nordic Orthopaedic Federation



Published online: 24 Jan 2014.



Submit your article to this journal [↗](#)



Article views: 1211



View related articles [↗](#)



View Crossmark data [↗](#)



Citing articles: 3 View citing articles [↗](#)

Incomplete periacetabular acetabuloplasty

A one-stop procedure for developmental dysplasia of the hip

Belen Carsi¹, Sariyah Al-Hallao², Karim Wahed², Jonathan Page³, and Nicholas M P Clarke¹

¹University Hospital Southampton NHS Foundation Trust, Southampton; ²Heatherwood and Wexham Park Hospitals NHS Trust, Slough; ³University Hospital of North Durham, Durham, UK.
Correspondence NMPC: ortho@soton.ac.uk
Submitted 13-06-20. Accepted 13-11-29

Background — Residual acetabular dysplasia is one of the most common complications after treatment for developmental dysplasia of the hip. The acetabular growth response after reduction of a dislocated hip varies. The options are to wait and add a redirection osteotomy as a secondary procedure at an older age, or to perform a primary acetabuloplasty at the time of the open reduction to stimulate acetabular development. We present the early results of such a procedure—open reduction and an incomplete periacetabular acetabuloplasty—as a one-stop procedure for developmental dysplasia of the hip.

Patients and methods — We retrospectively reviewed the results obtained with 55 hips (in 48 patients, 43 of them girls) treated between September 2004 and February 2011. This cohort included late presentations and failures of nonoperative treatment and excluded unsuccessful previous surgical treatment (including closed reductions), neuromuscular disease, and other teratological conditions. Patients were treated once the ossific nucleus was present or when they reached one year of age. 31 cases were late presentations while 17 represented failures of nonoperative treatment. The mean age of the patients at surgery was 1.3 (0.6–2.6) years. The mean follow-up period was 4 (2–8) years. According to the IHDI classification, 1 was grade I, 9 were grade II, 13 were grade III, and 32 were grade IV.

Results — The mean acetabular index fell from 38 (23–49) preoperatively to 21 (10–27) at the last follow-up. There were no infections, nerve palsies, or graft extrusions. None of the cases required secondary surgery for residual acetabular dysplasia. 8 patients developed avascular necrosis (AVN) of grade II or more. The incidence of AVN was significantly associated with previous, failed nonoperative treatment. 1 patient developed coxa magna requiring shelf arthroplasty 4 years after the index procedure and 1 patient with lateral growth arrest required medial screw epiphysiodesis.

Interpretation — This incomplete periacetabular acetabuloplasty is a reliable adjunct to open reductions, and it is followed by

a rapid acetabular growth response that avoids secondary pelvic procedures. It is a one-stop surgery with predictable outcome that can be performed in 0.5- to 2.5-year-old children.

The treatment of children with developmental dysplasia of the hip (DDH) between 6–24 months of age is controversial. Many authors have advocated closed reduction, provided arthrographic concentricity is achieved. However, the prevalence of residual acetabular dysplasia in this age group ranges from 38% to over 80% (Roose et al. 1979, Luhmann et al. 2003, Albinana et al. 2003). Many of these children will need secondary procedures at a later date, mainly a pelvic osteotomy, to prevent degenerative disease (Wedge and Wasylenko 1979). Some surgeons favor open reduction, which provides an opportunity to address acetabular dysplasia at the same time. Intentional late open reduction (delayed until the appearance of the ossific nucleus or by 1 year of age) is considered to be safe, as it is associated with a lower rate of subsequent pelvic osteotomy and a reduced incidence of avascular necrosis (Bolland et al. 2010).

We present the early results of a novel but possibly reinvented acetabular intervention. The incomplete periacetabular acetabuloplasty (IPA) is performed simultaneously with open reduction and capsulorrhaphy. The aim of the procedure is to “ignite” acetabular growth following concentric reduction of the femoral head rather than to completely correct acetabular deficiency or to perform a redirection procedure. We believe that the addition of less aggressive acetabular growth stimulation surgery may restore a more normal femoral head/acetabular development in a shorter period by precipitating a remodeling cascade. Such a process would obviate the need for further and more interventional secondary reconstructive pelvic surgery to address residual acetabular dysplasia.

Patients and methods

Patients

The study involved 55 hips in 48 patients (43 girls) treated from December 2004 through February 2011. There were 7 bilateral cases.

All cases of idiopathic DDH that presented late or had failed nonoperative treatment were included in the study. They comprised dislocations, subluxations, or instability. Excluded were cases that had had unsuccessful previous surgical treatment, including closed reductions, and those dislocations associated with neuromuscular disease or teratological conditions. 2 patients who were lost to follow-up with less than 2 years of clinical data were also excluded from the study.

The right hip was affected in 29 cases and the left in 26. 31 cases were late presentations and 17 cases were from failure of nonoperative treatment with Pavlik harness. According to the IHDI classification, 1 was grade I, 9 were grade II, 13 were grade III, and 32 were grade IV.

The average age of the patients at surgery was 1.3 (0.6–2.6) years and the minimum follow-up period was 2 years: mean 4 (2–8) years.

Treatment

All cases were treated with open reduction and acetabuloplasty by the lead surgeon. In the failed nonoperative management group, surgical treatment was delayed until the appearance of the ossific nucleus or until 1 year of age, whichever came first. All cases underwent a week of preoperative gallows traction.

The operative protocol for all patients included an arthrogram, adductor tenotomy, and open reduction and acetabuloplasty, using an anterior approach to the hip joint through a bikini-line incision. After psoas tenotomy at the level of the lesser trochanter, a T-shaped capsulotomy was performed. The in-folded labrum was everted and preserved. The hypertrophied ligamentum teres was detached from the femoral head, the transverse ligament incised, and the pulvinar and any other obstructions to reduction removed. The femoral head was then easily reduced and maintained by capsulorrhaphy. After reflection of the periosteum, the outer table of the ilium, 0.5 cm above the capsular insertion and lateral acetabular ring epiphysis, was osteotomized in a curved fashion following the contour of the acetabulum. The osteotomy was always shorter in length and depth than other pericapsular osteotomies and produced minimal distal displacement. A synthetic graft (a small pellet of Osteoset (Wright Medical Technology, Arling-

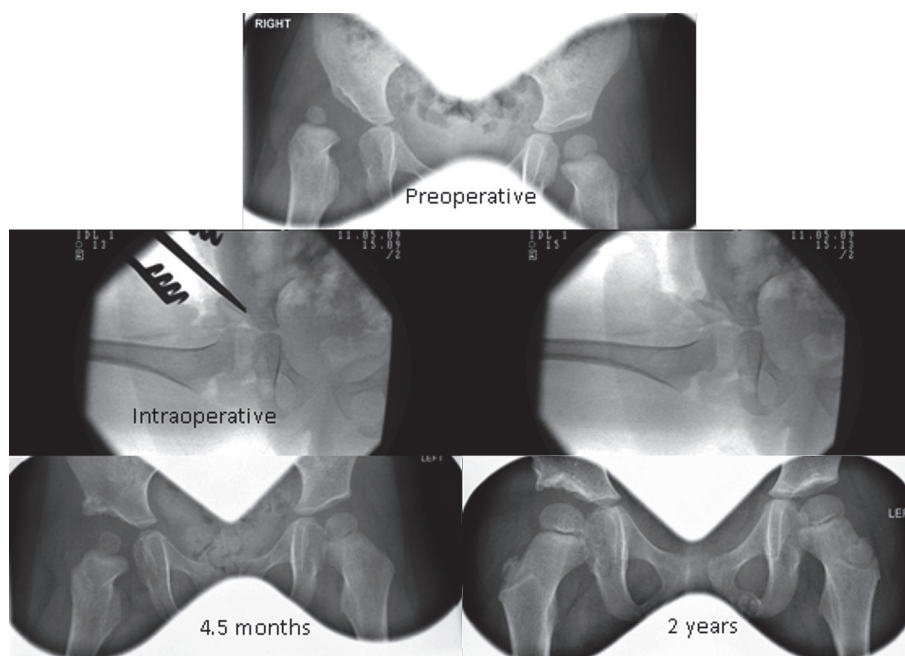


Figure 1. Comparison of preoperative and postoperative radiographs at 4.5 months and 2 years.

ton, TN) or similar compound) was inserted to maintain the tipped acetabular roof without additional fixation (Figure 1). Postoperative reduction of the hip was confirmed by using a limited computed tomographic imaging study.

This comprehensive surgical approach was completed by immobilization for 6 weeks in a spica cast in 100° flexion and 40–60° abduction, followed by 6 weeks in abduction broomstick plaster and a further 6 weeks in night-splints.

The patients were reviewed initially at 4-monthly intervals for the first year, 6-monthly intervals for the next year, and annually thereafter.

Radiographic assessment

Anteroposterior (AP) pelvic radiographs were reviewed. The International Hip Dysplasia Institute classification (personal communication with U. Narayan 2011) was used to grade the dysplasia preoperatively.

The acetabular index (AI) was measured to evaluate the correction of the acetabular dysplasia. The AI was determined preoperatively and at follow-up intervals after the immobilization period was completed. Ossific nucleus width and height (lateral and medial thirds) was also recorded to document the progression of ossific nucleus development compared to the contralateral side. These measurements were conducted by 2 independent observers.

Complications

Complications collated included redislocation, avascular necrosis (AVN), infection, nerve palsy, and the need for subsequent procedures. AVN was classified according to Kalama-

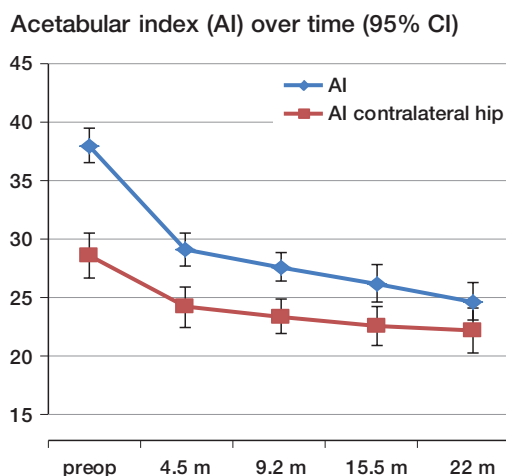


Figure 2. Progression of the acetabular index over time.

chi and MacEwen (1980) with grade I reflecting changes to the epiphysis, grade II indicating involvement of the lateral part of the growth plate, grade III indicating central physal damage, and grade IV indicating an injury to the whole physis and epiphysis. Grades II–IV were recorded as significant for AVN in this study.

Statistics

Statistical analysis was conducted using SPSS PASW 20.0 for Windows. Acetabular indices pre- and postoperatively followed a normal distribution. Fisher's exact test was used for categorical data.

Ethical approval

Approval from the institutional review board was not required, as this was a retrospective observational study.

Results

Acetabular index (AI)

The average preoperative AI was 38° (23–49). The first postoperative AI averaged 29° (17–40). AI continued to fall steadily over time, reaching an average of 21° (10–27) at 4 years post-acetabuloplasty (Figure 2).

The AI progression in those children who had surgery when aged 1.5 years or less ($n = 39$) was comparable to that in those who were more than 1.5 years old at the time of intervention ($n = 16$), with no statistically significant differences in the means for the 2 groups over time (p -values in the range 0.7–1.0).

Ossific nucleus development

The nucleus showed a progression towards correction of hypoplasia compared to the contralateral side (Figure 3).

Ossific nucleus difference (non-bilateral cases), mm

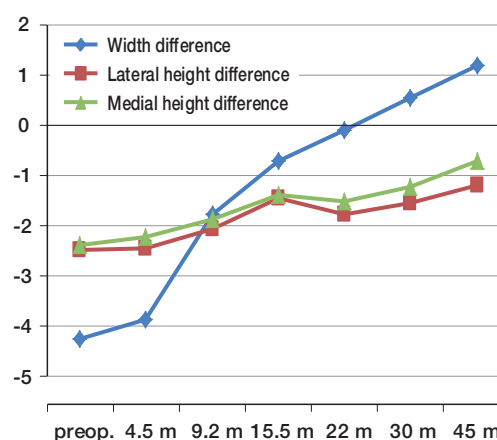


Figure 3. Temporal change in the mean difference in ossific nucleus width and height (lateral third and medial third) between the pathological and unaffected sides in non-bilateral cases.

Failed Pavlik and AVN rate

	AVN		Total
	No	Yes	
Late presentation	35	1	36
Failed Pavlik	12	7	19
Total	47	8	55

Complications

There were no redislocations, infections, nerve palsies, or graft extrusions. 8 patients developed AVN of grade II or above (5 grade II, 1 grade III, and 2 grade IV).

There was strong evidence of an association between the incidence of AVN and previous failed nonoperative treatment with Pavlik harness ($p = 0.002$). The estimated odds ratio was 20 (95% CI: 2.3–183), indicating a strong positive association (Table). However, there was no statistically significant association between AVN and preoperative IHDI classification or initial AI ($p = 0.6$ and $p = 0.3$, respectively). Also, those hips that developed AVN had a similar final AI to those that did not.

Those hips in which the ossific nucleus was present preoperatively had less incidence of AVN ($p = 0.02$).

1 patient developed coxa magna, necessitating a shelf arthroplasty 4 years after the index procedure. Another patient required medial screw epiphysiodesis after developing a lateral growth arrest at age 9 (7 years after the OR). No cases required secondary surgery for residual acetabular dysplasia.

Discussion

Treatment of children with DDH who fail nonoperative treatment with Pavlik harness or who present late is challenging. There are many options and protocols available, and the practitioner has to navigate controversial literature to opt for the management that can offer the best results, avoiding complications and the need for further procedures. A balance must be struck between a low avascular necrosis rate and minimal residual acetabular dysplasia. We found that the addition of an incomplete periacetabular acetabuloplasty at the time of open reduction for DDH rapidly normalized the AI without a substantial increase in avascular necrosis.

It is argued that early concentric reduction in DDH maximizes acetabular remodeling potential and reduces the need for secondary surgery to address residual acetabular dysplasia. The frequency of acetabular dysplasia quoted in the literature, for all ages, ranges from 17% to 80% (Roose et al. 1979, Weinstein 1987, Tucci et al. 1991, Malvitz and Weinstein 1994, Albinana et al. 2003). The age of initial reduction has been related to residual dysplasia (Lindstrom et al. 1979, Luhman et al. 2003), and also to the treatment chosen (closed vs. open reduction; Bolland et al. 2010). Remarkably, we did not find any difference in acetabular response between younger and older children.

The concept therefore of a “one-stop” open procedure in both late-presenting cases and intentionally delayed open reduction after failed Pavlik treatment is appealing, if it protects against the need for secondary surgery. This incomplete periacetabular acetabuloplasty has been developed as a technique for igniting acetabular growth while taking advantage of the exposure necessary for the open reduction, adding little extra surgical time or morbidity. We believe that it promotes acetabular growth by stimulating remodeling rather than immediate correction of deformity. Although pelvic osteotomies are usually recommended for children over 1.5 years due to the remodeling potential of the younger cohort, the reoperation rate after open reduction alone can be virtually eliminated by this additional step. Nonetheless, Dega osteotomies have been used successfully as an adjunct to open reductions in children as young as ours (Ruszkowski and Pucher 2005).

The intervention is probably not new. Albee (1915), Dickson (1924), Ghormley (1931), and other more recent authors (Wade et al. 2010) described similar incomplete periacetabular osteotomies. However, these procedures are all more interventional with substantial grafts inserted after roof displacement, and are intended to provide stability rather than stimulate growth. This incomplete periacetabular acetabuloplasty is less interventional in terms of point of entry of the osteotome, its extent and displacement. The periosteum is reflected at the acetabular rim and the entry point is just cephalad to the junction of cartilaginous labrum bone, but not as low as to produce chondroepiphyseal separation. Separation and displacement of the cartilage and labrum alone may lead to vascular injury and retardation

of acetabular development. It is therefore less aggressive in depth and length, and closer to the capsular edge than other widely used acetabuloplasties such as Tönnis, Dega, Nishio, and Pemberton, starting behind the anteroinferior iliac spine and stopping 1–2 cm from the sciatic notch while advancing just a few centimeters towards the triradiate cartilage. Our osteotomy leaves the posterior one-quarter and the inner two-thirds of the cortex intact. Allograft or bone substitutes are preferred to maintain the hinged displacement, as iliac crest autograft is less rigid and substantial in the age group under consideration. No fixation is required. When using Osteoset, the osteotomy opening is 3.3 mm. This produces a small acute correction of the AI. However, progressive improvement of the acetabular indices was noted until it normalized, in the majority of cases, less than 2 years after the index procedure. The pattern of ossific nucleus development matched the AI correction. There is therefore early evidence of remodeling within a time interval that would not compromise decision making in respect of the optimal time for a pelvic osteotomy. This contrasts with our previous series (Bolland et al. 2010), which demonstrated that—in cases requiring pelvic osteotomies—there was no significant ongoing improvement after 2 years.

Our preliminary results of the systematic addition of this procedure to open reductions demonstrate a low AVN (II–IV) rate compared to other series (e.g. Powell et al. 1986, Sankar et al. 2011), but lateral growth disturbance of the capital femoral epiphysis may be first evident by 9 or 10 years of age (Kim et al. 2000). Even so, this AVN rate is comparable to that in our previously reported series (Bolland et al. 2010), which implies that the addition of an incomplete periacetabular acetabuloplasty to open reductions does not make the femoral head more vulnerable to avascular necrosis. This comparison is meaningful, as other factors in our protocol (waiting for the appearance of the ossific nucleus and preoperative traction) remained constant. The only difference between the present series and our previously published results comparing open and closed reductions (Bolland et al. 2010) was the addition of an incomplete periacetabular acetabuloplasty. As previously described (Clarke et al. 2005), the presence of the ossific nucleus was associated with a significantly lower avascular necrosis rate while failed nonoperative treatment predisposed to it.

2 secondary procedures were required: 1 for coxa magna and another to address lateral growth arrest. No additional intervention was required to treat residual acetabular dysplasia. In our previous series (Bolland et al. 2010), 24 of 134 patients undergoing open reduction required a pelvic osteotomy.

In summary, it appears that an incomplete periacetabular acetabuloplasty as described is a safe adjunct to open reduction and obviates the need for secondary surgery. In patients older than 2.5 years, a pelvic osteotomy is probably necessary because of the reduced potential of the acetabular remodeling process ignited by the acetabuloplasty. However, the incomplete periacetabular acetabuloplasty described does not preclude the performance of a subsequent pelvic osteotomy.

BC: data collection, statistical analysis, and manuscript preparation. SAH and KW: blinded data collection from radiographs. JP: data collection. NC: senior author.

We thank Mrs Debbie Collins for her assistance in preparation of the manuscript.

No competing interests declared.

Albee F H. Bone-graft surgery. Philadelphia and London: W.B. Saunders; 1915.

Albinana J, Dolan L A, Spratt K F, et al. Acetabular dysplasia after treatment for developmental dysplasia of the hip. Implications for secondary procedures. *J Bone Joint Surg (Br)* 2003; 86: 876-86.

Bolland B J, Wahed A, Al-Hallao S, et al. Late reduction in congenital dislocation of the hip and the need for secondary surgery: radiologic predictors and confounding variables. *J Pediatr Orthop* 2010; 30: 676-82.

Clarke N, Jowett A J, Parker L. The surgical treatment of established congenital dislocation of the hip: results after planned delayed intervention following the appearance of the capital femoral ossific nucleus. *J Pediatr Orthop* 2005; 25 (4): 343-9.

Dickson F D. The operative treatment of old congenital dislocation of the hip. *J Bone Joint Surg* 1924; 6: 262-77.

Ghormley R K. Use of the anterior superior spine and crest of ilium in surgery of the hip joint. *J Bone Joint Surg* 1931; 13: 784-98.

Kalamachi A, MacEwen D. Avascular necrosis following treatment of congenital dislocation of the hip. *J Bone Joint Surg (Am)* 1980; 62: 876-88.

Kim H W, Morcuende J A, Dolan L A, Weinstein S L. Acetabular development in developmental dysplasia of the hip complicated by lateral growth disturbance of the capital femoral epiphysis. *J Bone Joint Surg (Am)* 2000; 82 (12): 1692-700.

Lindstrom J R, Ponset I V, Wenger D R. Acetabular development after reduction in congenital dislocation of the hip. *J Bone Joint Surg (Am)* 1979; 61: 112-8.

Luhman S J, Bassett G S, Gordon J E, et al. Reduction of a dislocation of the hip due to developmental dysplasia. Implications for the need for further surgery. *J Bone Joint Surg (Am)* 2003; 85: 239-43.

Malvitz T A, Weinstein S L. Closed reduction for congenital dysplasia of the hip. Functional and radiographic results after an average of thirty years. *J Bone Joint Surg (Am)* 1994; 76: 1777-92.

Powell E N, Gerratana F J, Gage J R. Open reduction for congenital hip dislocation: the risk of avascular necrosis with three different approaches. *J Pediatr Orthop* 1986; 6: 127-32.

Roose P E, Chingren G L, Klaaren H E, et al. Open reduction of congenital dislocation of the hip using Ferguson procedure. A review of twenty-six cases. *J Bone Joint Surg (Am)* 1979; 61: 915-21.

Ruszkowski K, Pucher A. Simultaneous open reduction and Dega transiliac osteotomy for developmental dislocation of the hip in children under 24 months of age. *J Pediatr Orthop* 2005; 25: 695-701.

Sankar W N, Young C R, Lin A G, Crow S A, Baldwin K D, Moseley C F. Risk factors for failure after open reduction for DDH: a matched cohort analysis. *J Pediatr Orthop* 2011; 31 (3): 232-9.

Tucci J J, Kumar S J, Guille J T, Rubbo E R. Late acetabular dysplasia following early successful Pavlik harness treatment of congenital dislocation of the hip. *J Pediatr Orthop* 1991; 11 (4): 502-5.

Wade W J, Alhussainan T S, Al Zayed Z, Hamdi N, Bubshait D. Contoured iliac crest allograft interposition for pericapsular acetabuloplasty in developmental dislocation of the hip: technique and short-term results. *J Child Orthop* 2010; 4 (5): 429-38.

Wedge J H, Wasylenko M J. The natural history of congenital disease of the hip. *J Bone Joint Surg (Br)* 1979; 61: 334-8.

Weinstein S L. Natural history of congenital hip dislocation (CDH) and hip dysplasia. *Clin Orthop* 1987; (225): 62-76.