

# Degeneration of the Acromioclavicular Joint: A Morphological Study

Claes J. Petersson

**To cite this article:** Claes J. Petersson (1983) Degeneration of the Acromioclavicular Joint: A Morphological Study, Acta Orthopaedica Scandinavica, 54:3, 434-438, DOI: [10.3109/17453678308996597](https://doi.org/10.3109/17453678308996597)

**To link to this article:** <https://doi.org/10.3109/17453678308996597>



Published online: 08 Jul 2009.



Submit your article to this journal [↗](#)



Article views: 1704



View related articles [↗](#)



Citing articles: 8 View citing articles [↗](#)

## DEGENERATION OF THE ACROMIOCLAVICULAR JOINT

### *A Morphological Study*

CLAES J. PETERSSON

Department of Orthopaedic Surgery, Malmö General Hospital (University of Lund), Malmö, Sweden

One hundred and sixty-eight acromioclavicular joint dissections were performed on 85 cadavera, 46 men and 39 women, with an average age of 69, ranging from 18 to 92. The intra-articular discs and the joint cartilages were scrutinized and degenerative changes were graded macroscopically. An age related disintegration of the disc and the joint cartilages was found. After the age of 70 maximum degeneration was very common.

*Key words:* acromioclavicular joint; cartilage; degeneration; shoulder

Accepted 17.ix.82

De Palma (1957) found that the first regressive changes in the acromioclavicular joint occurred in the second decade of life and thereafter rapidly increased with age. After 50 all joints were to some degree affected – the acromioclavicular worse than the sternoclavicular joints. Petersson & Redlund-Johnell (1983) found in a radiological study a reduction of the acromioclavicular joint space with age in standard antero-posterior projections of normal adults. After 60 an acromioclavicular joint space of 0.5 mm is not abnormal. The purpose of the present study was to elucidate the anatomical basis of the observed gradual reduction of the joint space by examining the acromioclavicular joint cartilages in cadavera of various ages.

### MATERIAL AND METHODS

One hundred and sixty-eight acromioclavicular joints of 85 cadavera, 46 men and 39 women, aged  $69 \pm 15$  (mean  $\pm$  S.D.) and with an age distribution according to Figure 1, were dissected. The cadavera were randomly selected in the Departments of Forensic Medicine and Pathology at the Malmö General Hospi-

tal. Most had died from cardiovascular disease or malignant disease, four had a history of shoulder complaint but none according to the case stories, had suffered from trauma or disease of the acromioclavicular joint. Most of the departed had been retired from work for years and information about their former occupation was often incomplete. In one woman, age 78, only the left shoulder and in another woman, age 52, only the right shoulder was dissected, in the re-

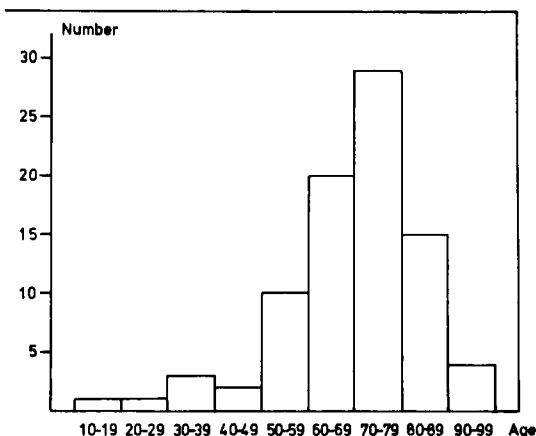


Figure 1. Age distribution.

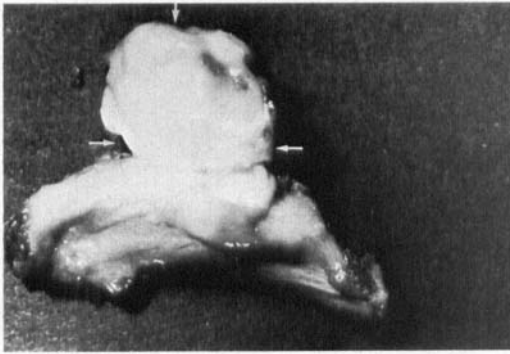


Figure 2. The acromial end of a normal acromioclavicular joint of a man, age 30. A complete disc, indicated by arrows, is elevated.

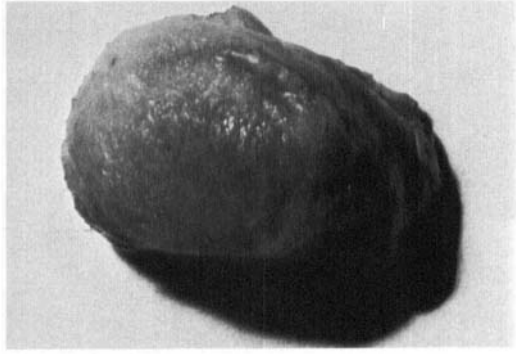


Figure 4. Normal cartilage on the clavicular end of a woman, age 71.

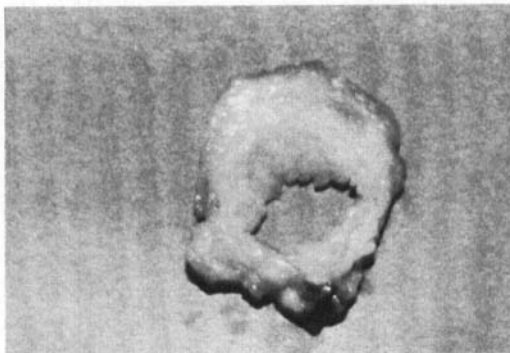


Figure 3. A meniscoid disc excised from the acromioclavicular joint of a woman, age 52. Note some fraying of the disc edges.




Figure 5. Grade I degeneration of the cartilage on the clavicular end of a man aged 77. Superficial blister formation and spotty fragmentation.

mainder of the cadavera both shoulders were scrutinized.

The acromioclavicular joints were exposed so that the intra-articular structures were clearly visible.

In each joint the intra-articular disc was examined and, depending on its condition, classified into one of the following groups:

1. Complete disc (Figure 2).
2. Meniscoid disc (Figure 3) with a central perforation and degenerative signs. In early degeneration only some fraying of the disc edges near the central hole was seen. In more advanced stages of degeneration the whole disc was involved with fraying and fibrillation.
3. Absent disc. In these cases only tiny remnants of the disc could be identified near its capsular insertion.

The cartilages of the acromial and clavicular joint surfaces were scrutinized. Macroscopic signs of degeneration were recorded and the joint-cartilages were classified into one of the following groups depending on the severity of impairment:

Normal cartilages (Figure 4); no degenerative signs.

Grade I degeneration (Figure 5); superficial degenerative signs with blister formation and some fragmentation.

Grade II degeneration (Figure 6); deep degeneration with cartilage fragmentation, blister formation and penetrating ulceration of the joint surface in irregularly shaped areas.

Grade III degeneration (Figure 7); full thickness cartilage degeneration denuding the subchondral bone of more than 50 per cent of the joint surface. Osteophytes on the inferior joint margins larger than 2 mm were registered.

## RESULTS

Complete discs were found in eight acromioclavicular joints, meniscoid discs in 112 and the discs were absent in 48 joints. The complete discs were

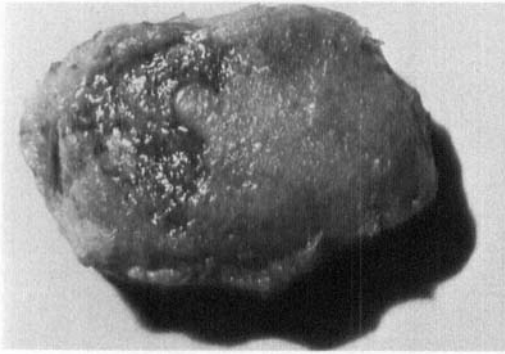


Figure 6. Grade II degeneration of the clavicular end of a man aged 77. Blister formation and deep ulceration of the cartilage in an irregularly shaped area.


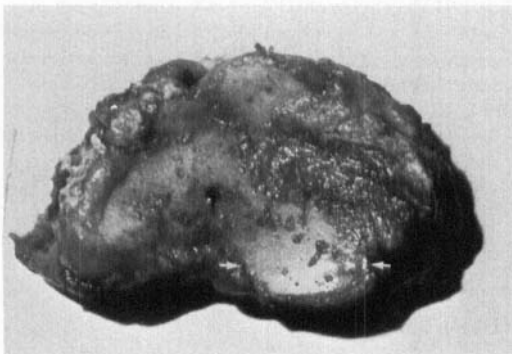


Figure 7. a, The clavicular end of a woman aged 80. Grade III degeneration with the subchondral bone denuded and only tiny rests of degenerated cartilage. Osteophyte indicated by arrows.



b, The acromial end of the same joint. Identical degree of degeneration. Distally pointing osteophyte indicated by arrows.

Table 1. Cartilage in 168 acromioclavicular joints

| Cartilage                 | n  | Average age<br>± S.D. | t-test      |
|---------------------------|----|-----------------------|-------------|
| Normal                    | 19 | 47±19                 |             |
| Grade I<br>degeneration   | 25 | 65±10                 | $P < 0.001$ |
| Grade II<br>degeneration  | 60 | 69±11                 | NS          |
| Grade III<br>degeneration | 64 | 77± 9                 | $P < 0.001$ |

found in the younger subjects but one man, age 78, had a complete disc in one acromioclavicular joint and a meniscoid disc in the other. There was no age difference between the subjects who had meniscoid discs and those in whom the discs were absent.

The joint cartilages showed degenerative changes of increasing severity with age according to Table 1. There was a highly significant age difference between acromioclavicular joints with normal cartilages and those with degeneration of grade I ( $P < 0.001$ , *t*-test). However, the oldest subject with normal acromioclavicular joint cartilages was the aforementioned man of 78, who also had a complete disc.

The age difference between joints with cartilage degeneration of grades I and II was non-significant whereas individuals with acromioclavicular joints with grade III degeneration were significantly older than those with grade II degeneration ( $P < 0.001$ ). The youngest subject with grade III degeneration was a woman, aged 52.

In 146 acromioclavicular joints the cartilage condition was the same on the right and the left side. In eight cadavera the cartilage degeneration was one grade more severe in the right acromioclavicular joint and in 11 cadavera the degeneration was one grade more severe in the left. In two cadavera the cartilage condition on the right and the left side differed two grades, being worst on the right side in one subject and on the left side in the other.

The degenerative changes often seemed to have a tendency to be more pronounced on the clavicular than on the acromial joint surface espe-

cially in joints with cartilage degeneration of grade I or III. However, the difference could not be quantified macroscopically.

In eight joints with a complete disc the joint cartilages were normal and in the remainder of the joints with normal cartilages the degenerative changes of the meniscoid discs were less pronounced than in the joints with cartilage degeneration. In joints with cartilage degeneration of grade II or III the discs were severely degenerated or absent.

Distally pointing osteophytes were recorded in 36 acromioclavicular joints. In 16 joints the osteophytes were found only on the clavicular side of the joint, in five they were present on the acromial side and in 15 joints osteophytes were encountered on both sides. The osteophytes were found in 18 acromioclavicular joints with cartilage degeneration of grade III, in 13 joints with degeneration of grade II and in five joints with degeneration of grade I. No osteophytes were registered in joints with normal cartilage.

## DISCUSSION

The results of the present investigation suggest that the anatomical basis of the radiologically observed age-related narrowing of the acromioclavicular joint space (Petersson & Redlund-Johnell 1983) is a gradual disintegration of the joint cartilages (Figure 8). It is evident from the study that this cartilage degeneration is age dependent. This is in accordance with the results of DePalma (1957). He found regressive changes in the acromioclavicular joint as early as in the second decade of life in some cases and after 50 this was a constant finding. In the present study, macroscopically normal joint cartilages were frequently recorded in joints of 30–50-year-old subjects and occasionally in joints from older subjects. However, after 60, the cartilage disintegration seems to be rapid and after 70 the changes are very common.

DePalma (1957) described two anatomical variations of the acromioclavicular disc; the complete disc and the incomplete or meniscoid form. The results of the present study suggest that the meniscoid disc is the consequence of regressive

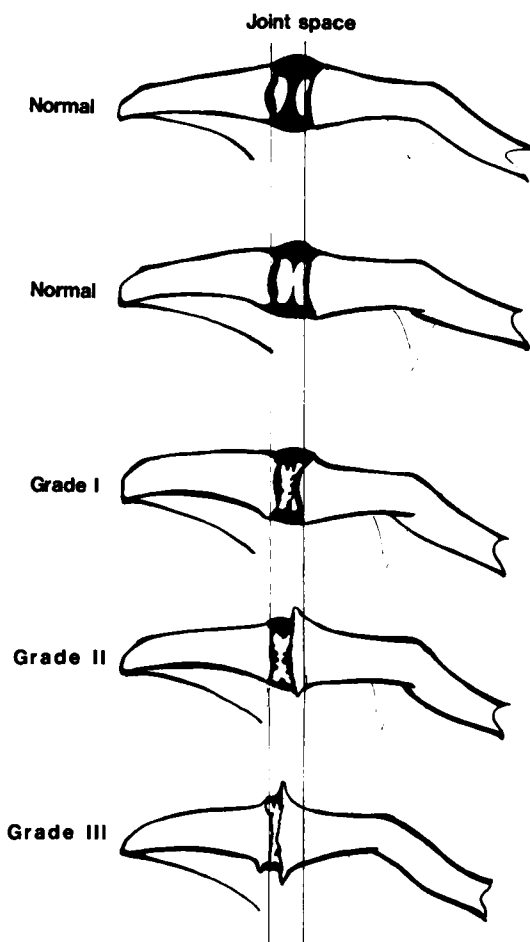


Figure 8. Relation between joint space and joint cartilage.

changes in a complete disc as the meniscoid discs even from young subjects always showed some signs of degeneration, such as fraying of the disc edges. In joints with a complete disc the joint cartilages were always registered as normal including in one old subject, age 78. The explanation for this might be that the disc has a protective function in completely separating the joint surfaces from each other and acting as an absorber of attritive forces. In joints with cartilage degeneration of grade II or grade III the discs were always severely degenerated and in 48 joints (29 per cent) the disintegration had reached a maximum level with only a circular tab of disc remaining. This seems to suggest that the degen-

eration of the disc precedes that of the cartilages. Marginal lipping with distally pointing osteophytes became increasingly frequent with increasing changes of the joint cartilages.

The patient histories in a randomly selected autopsy series will provide poor information – this was true also in the present series – particularly information about former occupation of the departed was often incomplete. Also, information about shoulder disability during lifetime was scanty. Four cases had a history of shoulder distress but, according to their case stories, none of them had suffered from dysfunction of their acromioclavicular joints. This may be true, but several authors have pointed out that the acromioclavicular joint has a tendency to be overlooked in patients with shoulder disability (Heck & Chandler 1955, Worcester & Green 1968, Zanca 1971).

The results of the present study seem to indi-

cate that a gradual degeneration of the acromioclavicular joints is part of the normal aging process and in most individuals not associated with discomfort or pain.

## REFERENCES

- DePalma, A. F. (1957) Degenerative changes in the sternoclavicular and acromioclavicular joints in various decades. C. C Thomas, Springfield, IL.
- Heck, C. V. & Chandler, F. A. (1955) Diagnosis and treatment of pain in the acromio-clavicular joint. *J. Am. Geriat. Soc.* **3**, 993–996.
- Petersson, C. J. & Redlund-Johnell, I. (1983) Joint space in normal acromioclavicular radiographs. *Acta Orthop. Scand.*, in press.
- Worcester, J. N. & Green, D. P. (1968) Osteoarthritis of the acromioclavicular joint. *Clin. Orthop.* **58**, 69–73.
- Zanca, P. (1971) Shoulder pain: involvement of the acromioclavicular joint (analysis of 1,000 cases). *Am. J. Roentgenol.* **112**, 493–506.

Correspondence to: Claes Petersson, M.D., Department of Orthopaedic Surgery, Malmö General Hospital, S-214 01 Malmö, Sweden.