



Operative Treatment by External Fixation for Polyostotic Fibrous Dysplasia in The Elbow Joint.

Shigetsune Matsuya, Masahito Hatori, Masami Hosaka, Katsu Ito, Osamu Dohi, Mareyuki Endo & Shoichi Kokubun

To cite this article: Shigetsune Matsuya, Masahito Hatori, Masami Hosaka, Katsu Ito, Osamu Dohi, Mareyuki Endo & Shoichi Kokubun (2006) Operative Treatment by External Fixation for Polyostotic Fibrous Dysplasia in The Elbow Joint., Upsala Journal of Medical Sciences, 111:2, 269-274, DOI: [10.3109/2000-1967-056](https://doi.org/10.3109/2000-1967-056)

To link to this article: <https://doi.org/10.3109/2000-1967-056>



Published online: 12 Jul 2009.



Submit your article to this journal [↗](#)



Article views: 173



View related articles [↗](#)



Citing articles: 1 View citing articles [↗](#)

Operative Treatment by External Fixation for Polyostotic Fibrous Dysplasia in The Elbow Joint. A Case Report

¹Shigetsune Matsuya, ¹Masahito Hatori, ¹Masami Hosaka, ¹Katsu Ito, ²Osamu Dohi, ³Mareyuki Endo and ¹Shoichi Kokubun

¹Department of Orthopaedic Surgery, and ³Department of Pathology, Tohoku University School of Medicine, 1-1 Seiryomachi, Aobaku, Sendai 980-8574, Japan, ²Orthopaedic Surgery, Tohoku Kosai Hospital, 3-11 Kokubuncho 2 chome, Aobaku, Sendai 980-0803, Japan

ABSTRACT

Fibrous dysplasia is a condition in which normal skeletal bone changes into fibroblastic stroma and immature bone. We report our experience of a unilateral external fixator applied for the treatment of polyostotic fibrous dysplasia arising in the elbow.

The patient was a 38 year-old man. His main complaint was left elbow pain and a mass, which increased in size. The histological diagnosis from the needle biopsy was fibrous dysplasia. An articulated unilateral external fixator was used for immobilization. The lesions in the left distal humerus and proximal ulna were curetted and cancellous bone was packed into the cavity. An external fixator (Elbow Fixator, Orthofix Inc., McKinney, USA) was applied from the proximal humeral shaft to the distal ulnar shaft for postoperative tentative immobilization and preservation of the affected elbow joint movement.

At two years after the operation, the range of motion of the affected elbow was 90 degrees in flexion and -35 degrees in extension. The range of motion in pronation and supination of the left forearm was normal. No evidence of recurrence was noted at two years after surgery. The merits of using an external fixator were: an earlier start of range of motion exercises, and a decrease in the risk of tumor dissemination.

INTRODUCTION

Fibrous dysplasia is a condition in which normal skeletal bone changes into fibroblastic stroma and immature bone. The operative indication for fibrous dysplasia is

Received 19 September 2005

Accepted 4 October 2005

impending fracture or severe pain. Tumor curettage and bone grafting is usually performed for the treatment of fibrous dysplasia. Reconstruction after massive curettage of a lesion is very demanding. There have been few reports about the surgical treatment for massive osteolysis and multiple bone involvement by fibrous dysplasia in the elbow. We report our experience of a unilateral external fixator applied for the treatment of polyostotic fibrous dysplasia arising in the left elbow involving both the distal humerus and proximal ulna.

CASE

The patient was a 38 year-old man. His main complaint was left elbow pain. There was no evidence of McCune-Albright syndrome. He felt pain in the elbow already at age 30 when he lifted heavy objects. His left elbow mass gradually increased in size.

On initial physical examination, a 5cm x 4cm sized, hard bony mass was observed in the left upper arm lateral epicondyle. The range of motion of the left elbow was 90 degrees in flexion and -30 degrees in extension. Pronation and supination were not restricted. Plain radiography demonstrated an 8.0 x 6.5cm sized radiolucent lesion with a ground glass appearance and marginal sclerosis in the left humeral condyle. Similarly, a 6.5 x 2.0cm sized radiolucent lesion in the left proximal ulna and a 2.0 x 1.0cm sized in the left proximal radius were observed (Fig.1). Computed tomography (CT) (Toshiba Medical Systems Co., Ltd., Tokyo, Japan) showed osteolytic lesions in the left distal

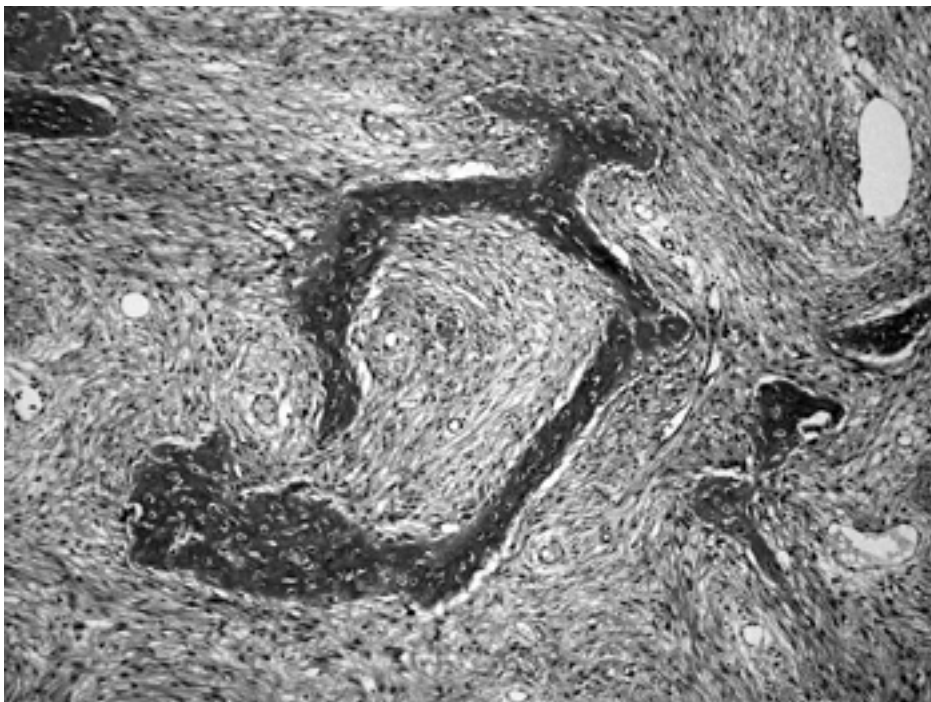


Fig. 1. Histological findings of the needle biopsy. A spindle cell fibrous tissue background and woven bone with a “Chinese characters” pattern were observed microscopically.

humerus. Magnetic resonance imaging (MRI) (GE Yokogawa Medical Systems, Ltd., Tokyo, Japan) showed a cystic change of the distal humerus. The distal humeral bone cortex was extremely thin and the cancellous bone changed into lobulus images on T2WI. Secondary aneurismal bone cyst (ABC) changes were suspected. Skeletal scintigraphy revealed high uptake lesions not only in the elbow but also in the left long finger from the metacarpal bone to the distal phalange. The histological diagnosis was fibrous dysplasia with secondary ABC (Fig.2). Operative treatment was chosen because of the enlargement of the tumor size and the high risk of pathological fractures of the humerus and/or ulna.

An articulated unilateral external fixator (Elbow Fixator, Orthofix Inc., McKinney, USA) was used to preserve the elbow joint function, since internal fixation may lead to tumor dissemination, and post-operative cast fixation can cause joint contracture. At first, we checked the center of the rotation axis of the elbow joint on anteroposterior view and

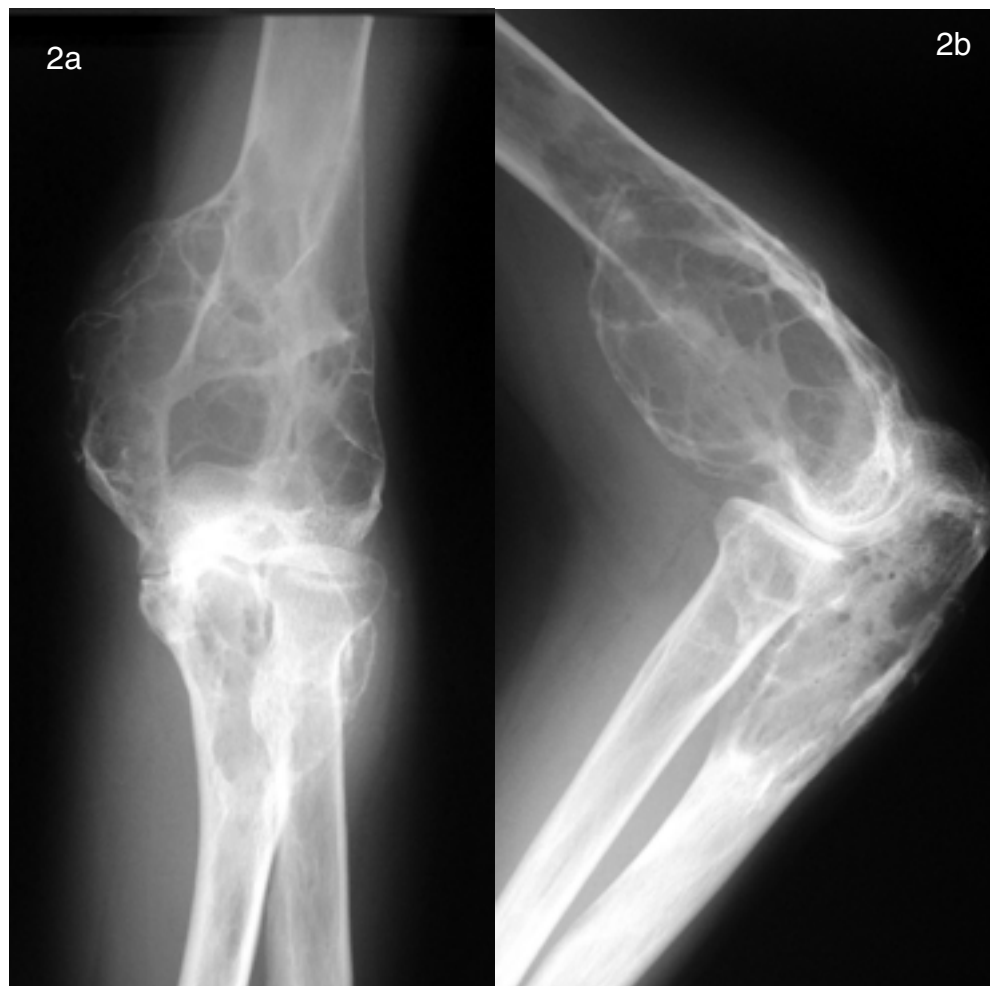

Fig. 2. Plain radiographs of the left elbow. Radiographs showed a ground glass appearance and marginal sclerosis. (a: anterior view; b: lateral view)

lateral view using an image intensifier. The lateral aspect of the humerus was exposed by blunt dissection in order to prevent damage to the radial nerve. The external fixator was fixed to the humeral normal bone shaft with three screws, kept away from the tumor lesion, as was the ulnar shaft. The lesions were curetted and cancellous bone from the ilium was packed into the cavity. The external fixator was applied. The external fixator's humeral and ulnar long axis crossed each other at the mechanical axis of the elbow joint. Finally, the ball-joints of the fixator were tightened with a wrench (Fig.3).

Postoperatively, range of motion exercises started two weeks after surgery, the external fixator was removed after six weeks, and the screws after two months. No evidence of recurrence was noted two years after surgery. The range of motion of the affected part of the left elbow was 90 degrees in flexion and -35 degrees in extension. The range of motion in pronation and supination of the left forearm was normal.

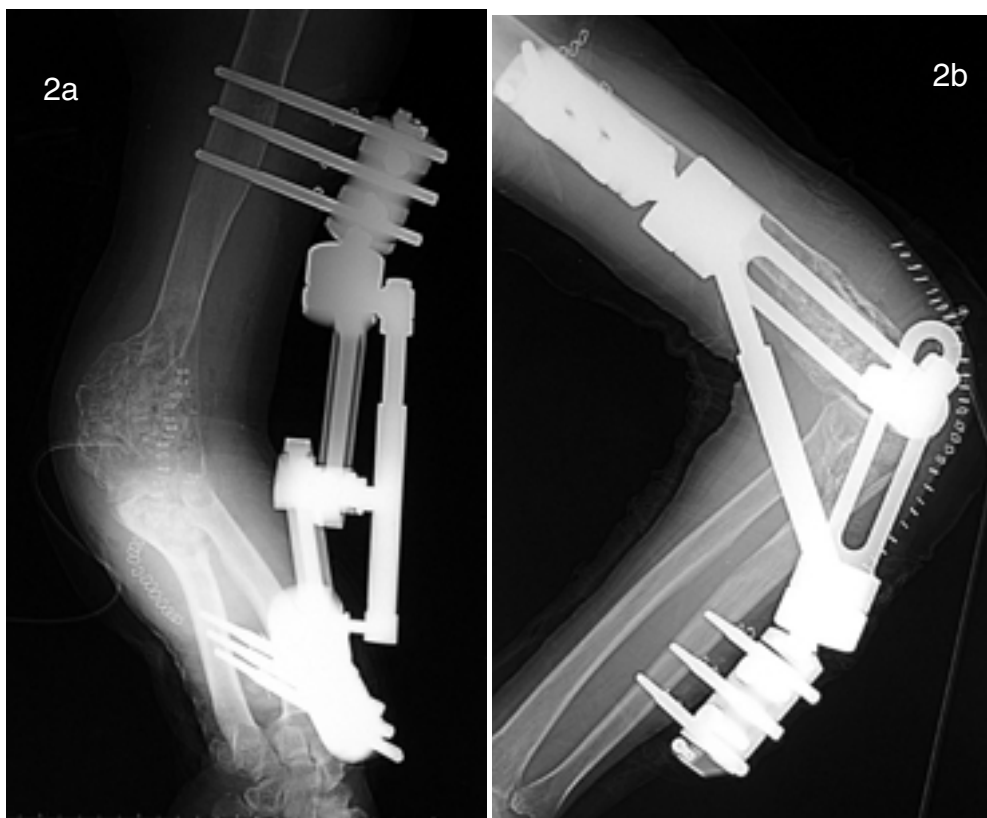


Fig. 3. Post operative plain radiographs of the left elbow. An external fixator was used for postoperative fixation (a: anterior oblique view; b: lateral view).

DISCUSSION

In fibrous dysplasia the bone matrices change into fibrous tissue or woven bone, and the strength of the bone is weaker than normal. The predominant complaint of fibrous dysplasia is local pain or deformities. Additionally, pathological fractures are not rare in patients with fibrous dysplasia (1,2). When the bone does not appear likely to fracture, conservative therapy is chosen for this disease (3-5). In most cases of pathological or impending fracture, surgical treatment is chosen (6-8). The surgical treatment is usually curettage and bone grafting.

An external fixator is sometimes employed for the treatment of bone tumors. The indication for its use includes pathological fractures due to bone tumors, and distraction osteogenesis for bone defects after resection or bone grafting. In addition, external fixation is sometimes used after primary oncological surgery, for the treatment of asymmetry (bone lengthening), pseudoarthrosis, infection, correction of angular deformity, and rescue surgery for knee prosthesis that has succumbed to bone reabsorption (9). For distraction osteogenesis, the Ilizarov method of external fixation is frequently used in the management of bone tumors (10,11).

We employed a hinged type of external fixation to preserve the elbow joint function. The Orthofix Elbow Fixator, an articulated unilateral external fixation device employed between the humerus and ulna, is designed to permit controlled movement around the center of rotation of the elbow joint. It allows immediate pronation and supination and early flexion and extension of the forearm, thus preventing post-operative stiffness.

As far as we know, there are few reports on the use of an external fixator for tumors in the elbow. In trauma cases, external fixation is used for fracture dislocations or complex elbow injuries (12,13), although the number of patients treated with an external fixator is small. This is because the indication for external fixation is limited to cases where conventional techniques have failed or could not be applied (12). A hinged type of external fixator is more suitable for such cases because of the minimal surgical intervention and earlier postoperative joint mobilization compared to the rigid type. Even with vigorous curettage followed by bone grafting, the affected elbow joint movements can be moderately preserved, and pronation and supination are not restricted.

In the present case, tumor lesions existed in the distal humerus, proximal ulna and proximal radius around the left elbow joint. Remarkably, the distal humeral bone cortex was extremely thin and fragile. Surgery was indicated because of the potential high risk of pathological fracture in the left humerus and/or ulna. At the operation, the elbow was judged not to be strong enough to hold the bone postoperatively after curettage and bone grafting. We used external fixation for the postoperative temporary fixation (14) and obtained good functional results. The merits of using an external fixation were an earlier start of the range of motion exercises than with cast fixation and a decreased risk of tumor dissemination. The demerits were the inconvenience in daily life and the possibility of pin infection.

REFERENCES

1. Enneking WF, Gearen PF (1986). Fibrous dysplasia of the femoral neck. Treatment by cortical bone-grafting. *J Bone Joint Surg Am* 68: 1415-22.
2. Parekh SG, Donthineni-Rao R, Ricchetti E, Lackman RD (2004). Fibrous dysplasia. *J Am Acad Orthop Surg* 12: 305-13.
3. Unni KK (1996). Conditions That Commonly Simulate Primary Neoplasms of Bone. Unni KK. *Dahlin's Bone Tumors: General Aspects and Data on 11,087 Cases*. Philadelphia. Lippincott-Raven. 367-76.
4. Isefuku S, Hatori M, Ehara S, Hosaka M, Ito K, Kokubun S (1999). Fibrous dysplasia arising from the calcaneus. *Tohoku J Exp Med* 189: 227-32.
5. Stephenson RB, London MD, Hankin FM, Kaufer H (1987). Fibrous dysplasia. An analysis of options for treatment. *J Bone Joint Surg Am* 69: 400-9.
6. Ozaki T, Sugihara M, Nakatsuka Y, Kawai A, Inoue H (1996). Polyostotic fibrous dysplasia. A long-term follow up of 8 patients. *Int Orthop* 20: 227-32.
7. Keijser LC, Van Tienen TG, Schreuder HW, Lemmens JA, Pruszczynski M, Veth RP (2001). Fibrous dysplasia of bone: management and outcome of 20 cases. *J Surg Oncol* 76: 157-66; discussion 67-8.
8. Onoda S, Hatori M, Yamada N, Hosaka M, Kokubun S (2004). A two- stage surgery for severe femoral neck deformity due to fibrous dysplasia: a case report. *Ups J Med Sci* 109: 123-9.
9. Canadell J, San-Julian M, Cara J, Forriol F (1998). External fixation in tumour pathology. *Int Orthop* 22: 126-30.
10. Stoffelen D, Lammens J, Fabry G (1993). Resection of a periosteal osteosarcoma and reconstruction using the Ilizarov technique of segmental transport. *J Hand Surg [Br]* 18: 144-6.
11. Erler K, Yildiz C, Baykal B, Atesalp AS, Ozdemir MT, Basbozkurt M (2005). Reconstruction of defects following bone tumor resections by distraction osteogenesis. *Arch Orthop Trauma Surg* 125: 177-83.
12. Stavlas P, Gliatis J, Polyzois V, Polyzois D (2004). Unilateral hinged external fixator of the elbow in complex elbow injuries. *Injury* 35: 1158-66.
13. Ruch DS, Triepel CR (2001). Hinged elbow fixation for recurrent instability following fracture dislocation. *Injury* 32 Suppl 4: SD70-8.
14. Nielsen D, Nowinski RJ, Bamberger HB (2002). Indications, alternatives, and complications of external fixation about the elbow. *Hand Clin* 18: 87-97.

Corresponding author: Masahito Hatori, M.D., Assistant Professor
 Department of Orthopaedic Surgery,
 Tohoku University School of Medicine
 1-1 Seiryomachi, Aobaku, Sendai, Japan 980-8574
 Fax: 81-22-717-7248, Tel: 81-22-717-7242
 mhato@mail.tains.tohoku.ac.jp